

Outcomes of Autologous Chondrocyte Implantation in Study of the Treatment of Articular Repair (STAR) Patients With Osteochondritis Dissecans

Brian J. Cole,^{*†} MD, COL (Ret) Thomas DeBerardino,[‡] MD, Robert Brewster,[§] MD, Jack Farr,^{||} MD, David W. Levine,[¶] MD, MPH, Carl Nissen,[#] MD, Prudence Roaf,[¶] MPH, and Kenneth Zaslav,^{**} MD

Investigation performed at Midwest Orthopaedics at Rush, Rush University Medical Center, Chicago, Illinois

Background: This is an analysis of the prospective Study of the Treatment of Articular Repair (STAR) to evaluate the effectiveness of autologous chondrocyte implantation (ACI) in a subset of adult patients with osteochondritis dissecans (OCD) knee lesions.

Hypothesis: Autologous chondrocyte implantation can improve clinical outcomes in patients with at least 1 chronic OCD lesion of the knee who failed a previous non-ACI cartilage repair treatment.

Study Design: Case series; Level of evidence, 4.

Methods: Forty patients with at least one failed non-ACI treatment for an OCD knee lesion received ACI in a multicenter study. The modified Cincinnati Knee Rating System, the Knee injury and Osteoarthritis Outcome Score (KOOS), and the Short-Form 36 Health Survey (SF-36) were used to assess patient outcomes at baseline and periodically to 48 months. Treatment failures, serious adverse events, and subsequent surgical procedures were recorded.

Results: Thirty-two (80%) patients completed the 48-month study. Autologous chondrocyte implantation treatment was successful in 85% of patients. Mean (\pm standard deviation) overall knee condition score (modified Cincinnati) was 3.1 ± 1.1 at baseline and 6.8 ± 2.0 at month 48. Clinically and statistically significant ($P < .001$) mean improvements from baseline to month 48 for the KOOS were as follows: 51.5 to 79.5 (pain), 54.8 to 77.9 (symptoms), 27.5 to 63.6 (sports and recreation ability), 63.5 to 86.7 (activities of daily living), and 21.9 to 59.6 (knee-related quality of life). The mean improvement ($P < .001$) in overall health assessed by the SF-36 was 35.4 to 45.5. Thirty-five percent ($n = 14/40$) of patients had a subsequent surgical procedure, most frequently debridement of the cartilage lesion. Treatment failure occurred in 6 of 32 (19%) patients.

Conclusion: Patients with OCD of the knee had statistically significant pain reduction and functional improvement for up to 48 months after ACI, despite the complexity and severity of the osteochondral lesions.

Keywords: articular cartilage repair; autologous chondrocyte implantation (ACI); Carticel; osteochondritis dissecans (OCD)

Osteochondritis dissecans (OCD) is a developmental condition that affects both bone and cartilage, initially involving the subchondral bone that can lead to articular cartilage damage and/or loss.¹⁴ Osteochondritis dissecans knee lesions are classified according to the patient's chronological age, location, surgical appearance, and radiographic findings.⁵ Acute or chronic symptomatic OCD occurs in the knees of both children and adults,⁸ with lesions further categorized as juvenile or adult depending on the maturation of the distal femoral physis.⁵ Common symptoms of OCD include pain and swelling with activity and focal tenderness at the site of the lesion.¹⁴ While repetitive trauma is thought to play a role in the development of OCD, particularly in athletes, the causes of the disorder are frequently unknown but may have a predisposing genetic component. The

majority of adult OCD lesions are thought to be the result of a persistent, unresolved juvenile OCD lesion.^{5,8,13,32}

Osteochondritis dissecans of the knee can be debilitating and challenging to treat,²⁵ especially in adults in whom surgical interventions are often necessary.¹³ Unlike juvenile OCD in which more than 50% of knee lesions can be healed with 6 to 18 months of nonoperative treatment,^{6,34} adult OCD lesions are more prone to instability and follow an unremitting course.¹³ Both juvenile and adult OCD lesions that do not heal may progress to premature degenerative joint disease, secondary to joint incongruity and abnormal wear patterns.⁸

Approaches to treating OCD vary and include nonoperative management, arthroscopic drilling, fragment excision, fragment fixation (bioabsorbable nails, pins, darts, or screws), microfracture, osteochondral autografts and allografts, or autologous chondrocyte implantation (ACI).^{††} Significant clinical improvements including reduced pain and

improved function after the treatment of OCD lesions of the knee with ACI have been demonstrated.^{1,15,16,21,27} Furthermore, a few studies have reported integrated repair tissue with hyaline-like structure with ACI.^{1,27,35}

The Study of the Treatment of Articular Repair (STAR) was designed to evaluate the use of ACI (Carticel [autologous cultured chondrocytes], Genzyme Corp, Cambridge, Massachusetts) in a study population of 154 patients who had failed a prior non-ACI cartilage repair procedure for symptomatic articular cartilage lesions of the knee.³⁸ The STAR demonstrated statistically significant and clinically important reductions in pain and improvements in function after ACI for the entire patient cohort.³⁸ Forty STAR patients had lesions due to chronic OCD, further contributing to the complexity and severity of the patients' disorder and increasing the degree of difficulty for successful treatment.³⁸ Because the STAR population included a relatively large number of patients with an OCD diagnosis, it provided a unique opportunity for valuable secondary analysis to further elucidate outcomes of ACI for adult OCD. Therefore, the purpose of this study was to conduct this subanalysis to assess whether ACI can reduce pain and improve function and activities in patients from the STAR with OCD lesions of the knee, all of whom had failed a previous non-ACI cartilage repair treatment.

MATERIALS AND METHODS

Study Design

The STAR was a rigorous Good Clinical Practice (GCP), prospective, multicenter, within-patient controlled clinical trial that assessed outcomes in patients treated with autologous cultured chondrocytes (Carticel, Genzyme Corp) over 48 months.³⁸ Details of the full study design, as well as a patient recruitment and follow-up consort diagram, have been previously reported by Zaslav et al.³⁸ Post hoc analyses were performed (and reported here) on a subset of 40 patients enrolled in the STAR with a diagnosed knee lesion due to OCD. Baseline information specific to

each patient and each lesion was collected. The date of OCD diagnosis was collected after study completion and based on patient operative notes and other medical records. Patients were followed prospectively after ACI for a period of 48 months and returned at 6-month intervals for a total of 8 follow-up visits.

The STAR clinical protocol was designed in consultation with the Food and Drug Administration (FDA) and monitored according to the principles of GCP. At each study site, the protocol was approved by an Institutional Review Board. All patients gave written informed consent before entering the study.

Participants

In the STAR, patients were at least 18 years of age and had at least 1 Outerbridge grade III or IV²⁴ (full-thickness) chondral lesion of the knee located on the medial (MFC) or lateral femoral condyle (LFC) or the trochlea.³⁸ All patients were required to have an inadequate response to at least 1 non-ACI surgical repair treatment within the 36 months before providing informed consent for the study.

An inadequate response to a prior treatment was determined if the patient and the surgeon both agreed that the patient's symptoms warranted surgical retreatment of the lesion and the patient reported an overall knee condition of 5 or less on the modified Cincinnati Knee Rating System^{4,15,22} at the time of consent. Exclusion criteria included previous ACI treatment on the ipsilateral knee; concurrent total meniscectomy or a history of total meniscectomy; grade III or IV lesions of areas other than the MFC, LFC, or trochlea (ie, tibia or patella); or widespread osteoarthritis or inflammatory arthritis in the affected knee.³⁸

Surgical Methods and Rehabilitation

Autologous chondrocyte implantation was performed according to standard surgical procedures.^{3,7,10,18} Briefly, a cartilage biopsy specimen was harvested and sent to Genzyme Corp's FDA-licensed facility, where the

*Address correspondence to Brian J. Cole, MD, Midwest Orthopedics at Rush, Rush University Medical Center, 1611 West Harrison Street, Suite 300, Chicago, IL 60612 (e-mail: bcole@rushortho.com).

†Midwest Orthopaedics at Rush, Rush University Medical Center, Chicago, Illinois.

‡University of Connecticut Health Center, Farmington, Connecticut.

§Northwest Orthopaedic Specialists, Spokane, Washington.

||St Francis Hospital and Health Centers and Indiana Surgery Center South, Indianapolis, Indiana.

*Genzyme Biosurgery, Cambridge, Massachusetts.

#Elite Sports Medicine, Connecticut Children's Medical Center, Farmington, Connecticut.

**Virginia Commonwealth University, Richmond, Virginia.

Presented at the 36th annual meeting of the AOSSM, Providence, Rhode Island, July 2010.

One or more of the authors has declared the following potential conflict of interest or source of funding: This study was sponsored by Genzyme Corp, who also funded the medical writing support and statistical analyses. Dr Cole has received research support from Arthrex, DePuy, and Zimmer; is a consultant for Genzyme, Zimmer, Arthrex, DePuy, and DJ Ortho; and has received royalties from Arthrex and Elsevier. Dr DeBerardino has received research support from the Musculoskeletal Transplant Foundation and is a consultant for Arthrex. Dr Farr has received research, institutional, or nonresearch support from Advanced Biosurfaces, Biomet, Genzyme Biosurgery, RTI Biologics, Stryker, Zimmer, Smith & Nephew, Osiris, Eli Lilly, and Johnson & Johnson companies (DePuy, Mitek, and Advanced Technologies and Regenerative Medicine); is a consultant or advisory board member for Arthrex, Johnson & Johnson companies, Genzyme Biosurgery, Regen Meneflex, Stryker, Zimmer, Advanced Biosurfaces, VOT Arthroscopic Solutions, RTI Biologics Cartilage, and Prochon; has received royalties from Johnson & Johnson companies (DePuy/Mitek, DePuy Orthopaedic) and Stryker; and has stock/stock options in Advanced Biosurfaces and VOT Arthroscopic Solutions. Dr Nissen is on the speakers' bureau for Genzyme. Dr Levine and Mrs Roaf are employees of Genzyme. Dr Zaslav is a principal investigator (phase III trial) for Ivivi; is a member of the data safety monitoring board for Zimmer; is a consultant to Genzyme, Zimmer, and Bacterin; and is a member of the scientific advisory board of CartiHeal and OrthoSpace.

chondrocytes were isolated from the biopsy specimen and cultured in vitro to expand the chondrocyte population for implantation. The cells were then implanted into the cartilage defect, which was covered by a flap of autologous periosteal tissue (with the cambium layer facing the defect) that had been sutured and glued to the adjacent articular cartilage. Anterior cruciate ligament repair/reconstruction, partial meniscectomy, meniscal repair, and osteotomy were performed as necessary either staged or concurrent with ACI.

Outcome Measures

Data from several outcome scales were prospectively collected to assess patient-reported changes from baseline. The modified Cincinnati Knee Rating System^{4,15,22} was used to assess overall knee condition at baseline and 6, 12, 24, 36, and 48 months. Overall knee condition was based on a 10-point scale: poor (1, 2), fair (3, 4), good (5, 6), very good (7, 8), or excellent (9, 10).⁴ The Knee injury and Osteoarthritis Outcome Score (KOOS)³¹ subscales were used to evaluate pain, symptoms, sports and recreation ability, activities of daily living (ADL), and knee-related quality of life (QoL) at baseline and every 12 months thereafter. The Short-Form 36 Health Survey (SF-36)³⁶ was used to assess overall physical health at baseline and every 12 months thereafter. An additional end point that was reported in the primary STAR was a within-patient comparison of the survivorship (time to treatment failure) of the ACI procedure to that of the prior non-ACI procedure.

The study protocol defined the ACI procedure as a failure for patients who required surgical retreatment that violated the subchondral bone (eg, abrasion arthroplasty, microfracture, drilling, unicompartmental knee replacement, or total knee replacement), had reimplantation with autologous chondrocytes or removal of ACI, had complete delamination, or reported an overall modified Cincinnati knee condition score that failed to improve from baseline during 3 consecutive postoperative 6-month intervals.^{4,15,22}

Safety information was systematically collected. Serious adverse events (SAEs), including subsequent surgical procedures (SSPs) and/or treatment failures after ACI, were collected at each study visit and recorded on standardized case report forms. Serious adverse events included treatment failures as well as clinically significant diagnoses noted during an SSP on the index knee.

Statistics

All patients who received ACI and exhibited OCD lesions were included in an intent-to-treat analysis to assess outcome measures, including patients who were considered to have post-ACI treatment failures. The within-patient change from baseline to subsequent visits was determined for each patient-reported outcome measure. Logistic regression and Fisher exact tests were performed using appropriate 2-sided tests with $\alpha = .05$ (v8.1, SAS Institute, Cary, North Carolina).

TABLE 1
Patient and Lesion Characteristics at Baseline^a

Patient characteristics (n = 40 patients)	
Age, mean \pm SD, y	30.5 \pm 9.5
Men, n (%)	30 (75)
Body mass index, mean \pm SD, kg/m ²	27.5 \pm 4.8
Reason for seeking treatment, n (%)	
Pain	37 (92.5)
Function	34 (85.0)
Other symptoms	21 (52.5)
Baseline overall knee condition score, ^b mean \pm SD	3.1 \pm 1.1
Baseline pain score, ^b mean \pm SD	3.1 \pm 1.9
No. of prior surgeries, mean (range)	2.0 (1-5)
Lesion characteristics (n = 54 lesions)	
No. of lesions per patient, mean \pm SD	1.4 \pm 0.6
Size of primary lesion at implantation (after debridement), mean \pm SD, cm ²	5.4 \pm 4.6
Mean total lesion area implanted, mean \pm SD, cm ²	6.3 \pm 5.0
Location of primary lesions (n = 40), n (%)	
Medial femoral condyle	26 (65)
Lateral femoral condyle	11 (28)
Trochlea	3 (8)
Location of additional lesions (n = 14), n (%)	
Medial femoral condyle	5 (36)
Lateral femoral condyle	1 (7)
Trochlea	8 (57)

^aSD, standard deviation.

^bModified Cincinnati Knee Rating System.

RESULTS

Patient Disposition and Baseline Characteristics

Of the 154 patients in the overall STAR population, 40 (26%) patients had a primary lesion due to OCD (with a detached or unstable fragment) who had failed a prior procedure³⁸ and were analyzed herein; of these 40 patients entering the study, 32 (80%) patients completed the study. Of the patients who did not complete the study, all (n = 8) were lost to follow-up. The mean time of patient follow-up was 43.2 months (range, 18.0-52.8 months). For the entire OCD cohort (n = 40), the mean time from OCD diagnosis to implantation was 17.5 months (range, 3.2-72.3 months). Five of the 40 (12.5%) patients received the diagnosis of OCD lesions of the knee before the age of 18 years; their mean time from OCD diagnosis to implantation was 41.5 months (range, 17.8-72.3 months). The majority of OCD lesions (62.5%) were determined during an arthroscopy procedure, while the remainder was diagnosed with magnetic resonance imaging (MRI) (20%), radiographs (12.5%), or a combination of these techniques (5%).

Demographics and baseline outcome measure scores of patients with OCD lesions are summarized in Table 1. Patients had a mean age of 30.5 years and were predominantly male (75%), with a mean body mass index of 27.5 kg/m². Their primary reasons for seeking treatment were knee pain and loss of function. The mean number of prior knee surgeries was 2.0 (range, 1-5) per patient. One

TABLE 2
Number and Percentages of Patients
With Prior and Concurrent Procedures^a

Surgical Procedure Performed (n = 40 Patients)	n (%)
Failed prior non-ACI surgery on the studied lesion	
Debridement alone	20 (50)
Microfracture	9 (23)
Subchondral drilling	6 (15)
Abrasion arthroscopy	3 (8)
Marrow stimulation, unspecified	1 (2.5)
Bone graft	1 (2.5)
Osteochondral autograft	0
Chondroplasty	0
Concurrent procedure during the failed prior non-ACI surgery	
Loose body removal	17 (43)
Partial meniscectomy, lateral	4 (10)
Partial meniscectomy, medial	2 (5)
Synovectomy	2 (5)
Osteotomy	2 (5)
ACI biopsy harvest	2 (5)
Anterior cruciate ligament repair	1 (2.5)
Lateral release of patella retinaculum	1 (2.5)
Tibial osteotomy	1 (2.5)
Medial meniscal repair	1 (2.5)
Concurrent procedure during ACI	
Tibial tubercle osteotomy	2 (5)
Lateral release of patella retinaculum	1 (2.5)
Tibial osteotomy	1 (2.5)
Loose body removal	1 (2.5)
Bone graft	1 (2.5)

^aACI, autologous chondrocyte implantation.

patient had a prior bone graft, while another had a bone graft during ACI (Table 2).

The mean number of lesions (\pm standard deviation) per patient was 1.4 ± 0.6 (range, 1.0-3.0). The mean defect size of the primary lesion at implantation (after debridement) was 5.4 ± 4.6 cm² (range, 1.0-30.0 cm²), and the mean total lesion area implanted was 6.3 ± 5.0 cm² (range, 1.0-30.0 cm²). The majority (65%) of the primary lesions were located on the MFC (Table 1). Eleven of the 40 patients had 14 additional lesions; of these, the majority (57%) was located on the trochlea, and 7 (50%) were considered OCD. The 7 additional OCD lesions were in 5 patients; of these 5 patients, only 1 had 2 OCD lesions in the same location (MFC), while the others had their OCD lesions in different locations. All of the 7 additional OCD lesions were treated with ACI and were included in this analysis; only 1 of the 7 non-OCD lesions was treated with ACI but was not included in this analysis. The other 6 non-OCD lesions were not treated.

The most common failed prior non-ACI surgeries on the primary lesion (Table 2) included debridement alone (50%), microfracture (23%), and subchondral drilling (15%). The most common concurrent procedures performed during the failed prior non-ACI procedure (Table 2) were loose body removal (43%) and partial lateral meniscectomy (10%). Concurrent procedures during the ACI procedure

consisted of tibial tubercle osteotomy, lateral release of the patella retinaculum, tibial osteotomy, loose body removal, and bone graft (Table 2).

Outcome Measures

The mean modified Cincinnati Knee Rating System score for all ACI-treated patients with OCD lesions of the knee was 3.1 ± 1.1 (range, 1-5) at baseline and 6.8 ± 2.0 (range, 2-10) at 48 months of follow-up (Table 3 and Figure 1). The change from baseline to month 48 (3.8 ± 2.2), as well as the change from baseline to months 6, 12, 18, 24, and 36, was statistically significant ($P < .001$) (Table 3 and Figure 1). At baseline, the majority (36/40, 90%) of patients with OCD had an overall knee condition of poor to fair (score ≤ 4); at 48-month follow-up, the majority of patients (28/30, 93%) reported an overall knee condition of good to excellent (score ≥ 5) (Figure 2). Included in the 30 patients at 48 months are 3 patients who had failed treatment because of surgical retreatment that violated the subchondral bone; their scores before retreatment were 6 at 24 months (6 at 48 months), 5 at 24 months (6 at 48 months), and 3 at 36 months (8 at 48 months).

Analysis of all ACI-treated patients with OCD revealed statistically significant ($P < .001$) improvements from baseline to 48 months, and at all other follow-up time points, in the KOOS subscales of pain, symptoms, sports and recreation ability, ADL, and knee-related QoL (Table 3 and Figure 3). Mean improvements from baseline to month 48 for the 5 KOOS subscales were as follows: 28.0 (pain), 22.1 (other knee-related symptoms), 41.6 (sports and recreation), 22.6 (ADL), and 35.8 (knee QoL). The change from baseline to month 48 for overall health using the SF-36 was 9.9 ± 10.0 ($P < .001$). A last observation carried forward analysis was also performed and showed similar results to those reported using available data at each time point (see the Appendix, available in the online version of this article at <http://ajs.sagepub.com/supplemental/>).

Serious Adverse Events and Subsequent Surgical Procedures

Thirty-five percent of patients (14/40) had SSPs. By study convention, findings at these SSPs were recorded as individual SAEs; therefore, 35% (14/40) of patients also had an SAE (Table 4). The most common SAEs were the development of new areas of cartilage involvement (5/40, 12.5%), graft overgrowth (5/40, 12.5%), graft complication (4/40, 10.0%), chondromalacia (3/40, 7.5%), graft delamination (3/40, 7.5%), and arthrofibrosis (2/40, 5%). Additional areas of cartilage involvement included tibial plateau fibrillation and a trochlear flap (both occurring in 1 patient), new trochlear defect (2 cases), new-onset lesion of the anterior left knee (1 case), and a persistent MFC lesion (1 case). Graft complication included instances of "unstable cartilage flap," "delamination of the periosteal patch" (in 2 patients), and "fraying of graft." The most common SSPs in these 14 patients (Table 5) were debridement of the cartilage lesion (10/14, 71%) and loose body removal (3/14, 21%).

TABLE 3
Outcome Measures in Patients With Osteochondritis Dissecans After
Autologous Chondrocyte Implantation Over Time^a

Parameter	Baseline (n = 40)	6 mo (n = 38)	12 mo (n = 37)	24 mo (n = 36)	36 mo (n = 31)	48 mo ^b (n = 30)
Modified Cincinnati KOOS	3.1 ± 1.1	5.6 ± 1.6	6.5 ± 2.2	6.7 ± 2.0	6.4 ± 2.1	6.8 ± 2.0
Pain	51.5 ± 16.8	76.4 ± 15.4	77.7 ± 17.6 ^c	76.6 ± 15.4	79.5 ± 16.5	
Symptoms	54.8 ± 19.5	78.7 ± 13.1	76.8 ± 15.6	75.7 ± 15.2	77.9 ± 17.4	
Sports/recreation ^d	27.5 ± 22.1	55.3 ± 22.8	63.2 ± 27.1	60.8 ± 25.0	63.6 ± 25.9	
Activities of daily living	63.5 ± 19.3	87.1 ± 12.9	87.8 ± 13.4 ^c	87.5 ± 12.8	86.7 ± 15.2	
Quality of life	21.9 ± 14.4	46.0 ± 22.3	53.1 ± 25.0	50.2 ± 22.6	59.6 ± 22.3	
SF-36 physical component	35.4 ± 10.5 ^e	43.7 ± 8.7	45.9 ± 7.9	45.9 ± 7.7	45.5 ± 9.9	

^aValues expressed as mean ± standard deviation. Each parameter outcomes at all time points were significantly better than at baseline ($P < .001$, for all). KOOS, Knee injury and Osteoarthritis Outcome Score.

^bAlthough 32 patients were seen at the final study visit and characterized as study completers, only 30 patients completed the outcomes measures at 48 months follow-up.

^cn = 35.

^dFor Sports/recreation, the number of patients was 34 at baseline, 32 at 12 months, 33 at 24 months, 30 at 36 months, and 29 at 48 months.

^en = 39.

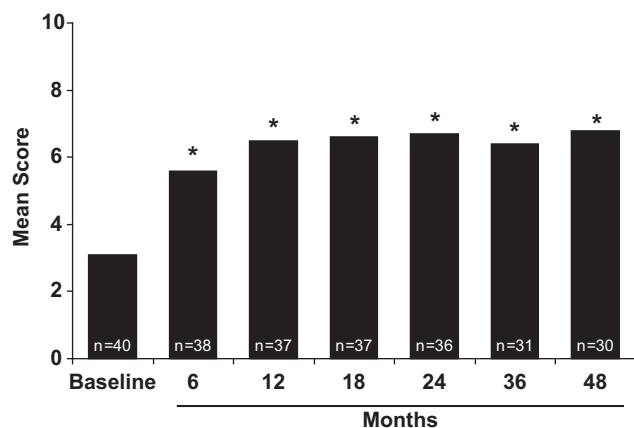


Figure 1. Mean scores for the modified Cincinnati Knee Rating System in all patients with osteochondritis dissecans after autologous chondrocyte implantation over time. Changes from baseline at all time points were significant ($*P < .001$).

Eighty-five percent (34/40) of the OCD patients did not meet the definition of treatment failure (treatment successes) at the end of the study, and 15% (6/40) of patients met the study definition of treatment failure. Of the patients who completed the study, 19% (6/32) met the study definition of treatment failure. Of these 6 patients, 3 patients required retreatment that violated the subchondral bone, and 3 patients reported an overall knee condition that failed to improve from baseline during 3 consecutive postoperative 6-month intervals. All of the patients who had a treatment failure completed the study. One of the 6 treatment failures occurred between 1 and 6 months after ACI, 4 occurred at a minimum of 18 months after ACI, and 1 occurred at more than 36 months after ACI. The survivorship results for the OCD cohort are similar to the previously reported overall STAR survivorship results. This indicates that the majority of OCD patients maintained improvement

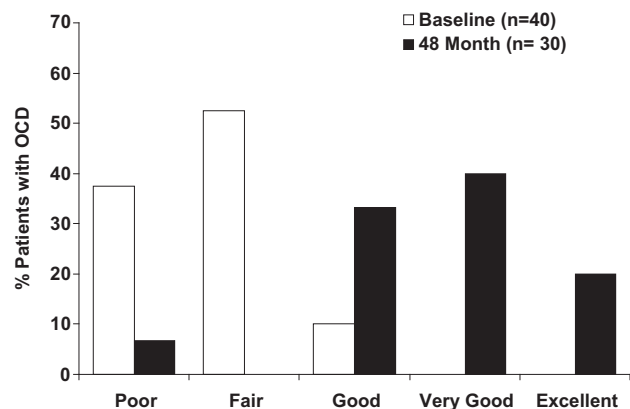


Figure 2. Categorical representation of modified Cincinnati Knee Rating System results. The percentage of patients within each overall condition at baseline and at 48 months is shown.

by the end of the 48-month follow-up in contrast to the shorter survivorship (<3 years) observed with the earlier non-ACI procedure in these same patients. Not all patients (n = 14) who had an SAE and SSP met the definition of treatment failure. Overall, 64% (9/14) of these patients did not meet the definition of treatment failure, with 12 of these patients having completed the 48-month study.

DISCUSSION

In this subanalysis of the prospective STAR, statistically significant and clinically relevant improvements were seen for patients with OCD knee lesions who failed at least 1 non-ACI cartilage repair procedure. Although these patients with chronic lesions can be extremely challenging to treat, significant improvements were seen in pain, symptoms, sports, knee-related QoL, and overall physical

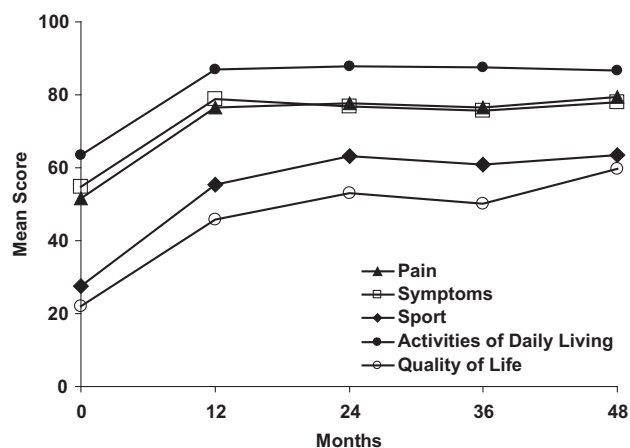


Figure 3. Mean scores for Knee injury and Osteoarthritis Outcome Score subscales in patients with osteochondritis dissecans after autologous chondrocyte implantation over time. All improvements from baseline to 48 months were significant ($P < .001$).

TABLE 4

Serious Adverse Events Reported for the Study Knee in Patients With Osteochondritis Dissecans

Event ^a	Patients (n = 40), n ^b (%)
Cartilage injury	5 (12.5)
Graft overgrowth	5 (12.5)
Graft complication	4 (10.0)
Chondromalacia	3 (7.5)
Graft delamination	3 (7.5)
Arthrofibrosis	2 (5.0)
Arthralgia	1 (2.5)
Arthropathy	1 (2.5)
Failure of implant	1 (2.5)
Joint adhesion	1 (2.5)
Loose body in joint	1 (2.5)
Medical device pain	1 (2.5)
Meniscus lesion	1 (2.5)
Osteoarthritis	1 (2.5)
Osteochondrosis	1 (2.5)
Procedural pain	1 (2.5)
Synovitis	1 (2.5)
Tendinitis	1 (2.5)
Wound infection	1 (2.5)

^aSerious adverse events occurred in 14 of 40 osteochondritis dissecans patients.

^bThe number of serious adverse events is not additive because patients may have more than 1.

health scores from baseline to 48 months by the KOOS and SF-36. Overall, 85% of patients were successfully treated with ACI. Using the modified Cincinnati Knee Rating System, the mean score for patients significantly improved from 3.1 at baseline to 6.8 after 48 months of follow-up. Of the patients who completed the study, the majority of patients reported good or excellent (score ≥ 5) overall knee conditions after 48 months.

TABLE 5
Subsequent Surgical Procedures,^a Regardless of Relationship, in Patients With Osteochondritis Dissecans

Intervention ^b	Patients (n = 40), n ^c (%)
Debridement of cartilage lesion	10 (25)
Loose body removal	3 (7.5)
Microfracture	2 (5.0)
Periosteal patch reattachment/ removal/tear	2 (5.0)
Partial delamination	1 (2.5)
Partial implant removal	1 (2.5)
Lysis of adhesions	1 (2.5)
Synovectomy/synovial plica excision	1 (2.5)
Tibial osteotomy	1 (2.5)
Other ^d	10 (25)

^aAll procedures that occurred within a surgical date in an index knee subsequent to autologous chondrocyte implantation.

^bSubsequent surgical procedures occurred in 14 of 40 osteochondritis dissecans patients.

^cThe number of subsequent surgical procedures is not additive because patients may have more than 1.

^dPatients with other procedures had hardware removal, scar tissue removal, incomplete delamination, medial femoral condyle (MFC) lesion, microfracture to new-onset trochlear lesion, cartilage biopsy, microfracture to new-onset defect, drainage and irrigation of antibiotic fluid removal of bursa, chondroplasty of MFC lateral tibia plateau, diagnostic arthroscopy, and minimal debridement and diagnostic arthroscopy.

Our study patients with OCD knee lesions with at least 1 failed non-ACI cartilage repair procedure can be difficult to treat because OCD lesion chronicity increases the severity of their disease. In this study population, heterogeneity of lesion chronicity was evidenced by the wide time span from OCD diagnosis to ACI treatment (3.2 to 72.3 months). Additionally, in 13% of patients, OCD was diagnosed before the age of 18 years, but they were not treated until adulthood. Two patients also had a prior or concurrent bone graft, providing further evidence of the severity of OCD in this patient population. Despite the severity and chronicity of their OCD lesions, patients in our study significantly improved with ACI.

These results are similar to the outcomes reported in other studies evaluating the use of ACI for OCD knee lesions and full-thickness chondral injuries.^{3,4,15,20,23,27} Overall, our results are consistent with the outcomes of an earlier study by Peterson et al,²⁷ where 58 patients with OCD knee lesions were treated with ACI. Similar to our study population, their cohort had a mean age of 26.4 years (range, 14-52 years), an average defect size of 5.7 cm², and a mean number of previous operations of 2.1 (range, 0-8).²⁷ However, more than 60% (35/58) of their patients had juvenile-onset OCD, while our cohort only had 13% (5/40) of patients with OCD diagnosed before the age of 18 years. After a mean duration of 5.6 years of follow-up, 91% of their patients had a good or excellent overall rating on the basis of a clinician evaluation, and significant improvements were observed on all outcome scales (Tegner-Wallgren, Lysholm, and Brittberg-Peterson visual analog scale). Treatment of these OCD knee lesions with

ACI was successful in 95% of cases, with only 3 treatment failures.²⁷

Finally, the success rate of ACI in our adult population (85%) was slightly lower compared with a study of 23 adolescent athlete knees treated with ACI, of which 60% were OCD.²⁰ This study by Mithofer et al²⁰ reported 96% of adolescents having good or excellent postoperative results after a mean duration of 47 months and no treatment failures. A better response in adults compared with adolescents would not be expected, given that a younger age has been identified as a positive predictor of good outcomes for a variety of knee surgeries.^{2,11,12,19} Additionally, patients with shorter preoperative intervals from diagnosis to treatment, as seen with adolescents, compared with longer preoperative intervals seem to have better functional outcomes for ACI.^{20,28}

Our results also appear to be comparable with those of studies where full-thickness chondral injuries (Outerbridge grades III and IV) are treated with ACI.^{3,4,15,23} For example, in a study of 100 full-thickness chondral lesions, patients reported a significant improvement in their overall condition at 5 years postoperatively.⁴ Overall, ACI treatment was successful in 87% of patients compared with our 15% failure rate.⁴ In this study by Browne et al,⁴ patients were 37 years of age and had a mean total defect size of 4.9 cm², and 70% of patients had at least 1 prior failed cartilage repair procedure, similar to our study; however, only 8 patients had OCD. In another recent study, 51 patients with non-OCD, large and complex cartilage lesions of the knee treated with ACI had significant improvements in activity, working ability, and sports after a mean follow-up of 30 months.²³

Osteochondritis dissecans lesions can be treated with various surgical treatments including debridement, drilling, loose body removal, arthroscopic reduction and internal fixation (ARIF), microfracture, osteochondral allografts, and ACI depending on the stability and size of the lesions. A recent study by Pascual-Garrido et al²⁵ evaluated the outcomes with various surgical procedures performed in 48 OCD knee lesions in patients aged 34 years (range, 20-49 years) with a mean defect size of 4.5 cm² and with no prior surgical treatment. The most commonly used surgical techniques were osteochondral allograft (16 cases), ARIF (15 cases), and loose body removal (9 cases); only 3 cases were treated with ACI.²⁵ Overall, 14% of surgeries resulted in clinical failure, but generally, significant improvements were observed on all outcome scales (Noyes, Tegner, Lysholm, International Knee Documentation Committee, KOOS, and SF-12) after an average follow-up period of 4.0 years.²⁵ However, patients treated with ARIF and loose body removal had a greater improvement in outcome scores than those treated with osteochondral allografts. Although it is difficult to compare between treatments in different studies, our patients had more severe scores at baseline for all 5 KOOS components, compared with the patients in the study reported by Pascual-Garrido et al,²⁵ but showed greater improvements in all KOOS components 36 months after ACI treatment. There were no other common measures between their study and ours.

Severe adverse events were observed in 35% of patients and most often consisted of cartilage injury and graft overgrowth. These same patients underwent SSPs, which most

often consisted of debridement of the cartilage lesion followed by loose body removal. In this study, the failure rate of ACI treatment in knee lesions of OCD patients was 15%, and only 5 of the 14 (36%) patients who had an SSP met the study definition for failure. Therefore, having an SSP or SAE was not equivalent to treatment failure in this study. The failure and SSP rates (15% and 35%, respectively) in this OCD sub-analysis were numerically lower than those observed in the total STAR population (24% and 49%, respectively).³⁸ Finally, survivorship and durability of clinical benefit after ACI performed on OCD lesions were comparable to the results observed in the overall STAR.³⁸

A limitation of this analysis is that it was not a randomized controlled study. However, there was insufficient justification for the investigators to repeat non-ACI procedures, given the extensive surgical history of the patients. However, the within-patient control design was an appropriate study design for a second-line indication in which the possibility of randomization to a prior failed surgical procedure is unacceptable. Other limitations of this study are that arthroscopic, imaging, and histological data and lesion depth were not collected for patients requiring ACI. Although lesion depth was not captured, surgeons did individually assess each lesion for appropriate treatment in addition to ACI, and bone grafts were performed when necessary. Furthermore, analysis of the OCD subpopulation was a secondary analysis, not defined at the STAR inception. Notwithstanding limitations, this study was a rigorous, prospective study with a high follow-up rate of 4 years, which provides valuable data to inform and support treatment decisions for adult OCD.

While our study did not include arthroscopic, radiographic, or histological structural assessments of the repair tissue, multiple studies show that the majority of ACI patients have repair tissue that is either consistent with normal hyaline cartilage or composed of both hyaline and fibrocartilage.^{1,21,27,29} Furthermore, a long-term study of repair tissue from patients with OCD knee lesions showed that most patients had hyaline cartilage of normal appearance 9 to 18 years after ACI treatment.³⁵ Although a study assessing repair tissue 1 year after ACI treatment by MRI and histological and immunohistochemical analyses found it to be inferior to surrounding healthy hyaline cartilage,²¹ other studies have observed that repair tissue of high quality requires at least 2 years to regenerate and mature.^{21,26,30}

In conclusion, the results of this study have shown that ACI is a viable treatment option for full-thickness OCD lesions of the knee in adults. Despite the complexity and severity of the chondral lesions in the subset of STAR patients with OCD who also failed at least 1 non-ACI cartilage repair procedure, the majority of patients had clinically relevant and statistically significant pain reductions and functional improvements for up to 48 months after ACI. Overall, the results of this study are consistent with the results reported from the total STAR population.³⁸

ACKNOWLEDGMENT

The authors acknowledge Dominique Verlaan, PhD, and Sally Meiners, PhD, from Precise Publications LLC for

providing medical writing support and Ty McClure, PhD, for providing statistical analysis. Also acknowledged is Jennifer Morawiak for assisting with data compilation.

REFERENCES

- Bentley G, Biant LC, Carrington RW, et al. A prospective, randomised comparison of autologous chondrocyte implantation versus mosaicplasty for osteochondral defects in the knee. *J Bone Joint Surg Br*. 2003;85:223-230.
- Blevins FT, Steadman JR, Rodrigo JJ, Silliman J. Treatment of articular cartilage defects in athletes: an analysis of functional outcome and lesion appearance. *Orthopedics*. 1998;21:761-767.
- Brittberg M, Lindahl A, Nilsson A, Ohlsson C, Isaksson O, Peterson L. Treatment of deep cartilage defects in the knee with autologous chondrocyte transplantation. *N Engl J Med*. 1994;331:889-895.
- Browne JE, Anderson AF, Arciero R, et al. Clinical outcome of autologous chondrocyte implantation at 5 years in US subjects. *Clin Orthop Relat Res*. 2005;436:237-245.
- Cahill BR. Osteochondritis dissecans of the knee: treatment of juvenile and adult forms. *J Am Acad Orthop Surg*. 1995;3:237-247.
- Cahill BR, Phillips MR, Navarro R. The results of conservative management of juvenile osteochondritis dissecans using joint scintigraphy. *Am J Sports Med*. 1989;17:601-606.
- Cole BJ, D'Amato M. Autologous chondrocyte implantation. *Oper Tech Orthop*. 2001;11:115-131.
- Detterline AJ, Goldstein JL, Rue JP, Bach BR Jr. Evaluation and treatment of osteochondritis dissecans lesions of the knee. *J Knee Surg*. 2008;21:106-115.
- Fonseca F, Balaco I. Fixation with autogenous osteochondral grafts for the treatment of osteochondritis dissecans (stages III and IV). *Int Orthop*. 2009;33:139-144.
- Fu FH, Zurakowski D, Browne JE, et al. Autologous chondrocyte implantation versus debridement for treatment of full-thickness chondral defects of the knee: an observational cohort study with 3-year follow-up. *Am J Sports Med*. 2005;33:1658-1666.
- Kish G, Modis L, Hangody L. Osteochondral mosaicplasty for the treatment of focal chondral and osteochondral lesions of the knee and talus in the athlete: rationale, indications, techniques, and results. *Clin Sports Med*. 1999;18:45-66, vi.
- Kocher MS, Micheli LJ, Yaniv M, Zurakowski D, Ames A, Adrignolo AA. Functional and radiographic outcome of juvenile osteochondritis dissecans of the knee treated with transarticular arthroscopic drilling. *Am J Sports Med*. 2001;29:562-566.
- Kocher MS, Tucker R, Ganley TJ, Flynn JM. Management of osteochondritis dissecans of the knee: current concepts review. *Am J Sports Med*. 2006;34:1181-1191.
- McCarty LP. Primary repair of osteochondritis dissecans in the knee. In: Cole BJ, Sekiya JK, ed. *Surgical Techniques of the Shoulder, Elbow, and Knee in Sports Medicine*. Philadelphia: Saunders Elsevier; 2008:517-526.
- Micheli LJ, Browne JE, Erggelet C, et al. Autologous chondrocyte implantation of the knee: multicenter experience and minimum 3-year follow-up. *Clin J Sport Med*. 2001;11:223-228.
- Micheli LJ, Moseley JB, Anderson AF, et al. Articular cartilage defects of the distal femur in children and adolescents: treatment with autologous chondrocyte implantation. *J Pediatr Orthop*. 2006;26:455-460.
- Millington KL, Shah JP, Dahm DL, Levy BA, Stuart MJ. Bioabsorbable fixation of unstable osteochondritis dissecans lesions. *Am J Sports Med*. 2010;38:2065-2070.
- Minas T. Autologous chondrocyte implantation for focal chondral defects of the knee. *Clin Orthop Relat Res*. 2001;391(Suppl):S349-S361.
- Mintzer CM, Richmond JC, Taylor J. Meniscal repair in the young athlete. *Am J Sports Med*. 1998;26:630-633.
- Mithofer K, Minas T, Peterson L, Yeon H, Micheli LJ. Functional outcome of knee articular cartilage repair in adolescent athletes. *Am J Sports Med*. 2005;33:1147-1153.
- Moriya T, Wada Y, Watanabe A, et al. Evaluation of reparative cartilage after autologous chondrocyte implantation for osteochondritis dissecans: histology, biochemistry, and MR imaging. *J Orthop Sci*. 2007;12:265-273.
- Noyes FR, Barber SD, Mooar LA. A rationale for assessing sports activity levels and limitations in knee disorders. *Clin Orthop Relat Res*. 1989;246:238-249.
- Ossendorf C, Steinwachs MR, Kreuz PC, et al. Autologous chondrocyte implantation (ACI) for the treatment of large and complex cartilage lesions of the knee. *Sports Med Arthrosc Rehabil Ther Technol*. 2011;3:11.
- Outerbridge RE. The etiology of chondromalacia patellae. *J Bone Joint Surg Br*. 1961;43:752-757.
- Pascual-Garrido C, Friel NA, Kirk SS, et al. Midterm results of surgical treatment for adult osteochondritis dissecans of the knee. *Am J Sports Med*. 2009;37(Suppl 1):125S-130S.
- Peterson L, Brittberg M, Kiviranta I, Akerlund EL, Lindahl A. Autologous chondrocyte transplantation: biomechanics and long-term durability. *Am J Sports Med*. 2002;30:2-12.
- Peterson L, Minas T, Brittberg M, Lindahl A. Treatment of osteochondritis dissecans of the knee with autologous chondrocyte transplantation: results at two to ten years. *J Bone Joint Surg Am*. 2003;85(Suppl 2):17-24.
- Peterson L, Minas T, Brittberg M, Nilsson A, Sjogren-Jansson E, Lindahl A. Two- to 9-year outcome after autologous chondrocyte transplantation of the knee. *Clin Orthop Relat Res*. 2000;374:212-234.
- Roberts S, McCall IW, Darby AJ, et al. Autologous chondrocyte implantation for cartilage repair: monitoring its success by magnetic resonance imaging and histology. *Arthritis Res Ther*. 2003;5:R60-R73.
- Roberts S, Menage J, Sandell LJ, Evans EH, Richardson JB. Immunohistochemical study of collagen types I and II and procollagen IIA in human cartilage repair tissue following autologous chondrocyte implantation. *Knee*. 2009;16:398-404.
- Roos EM, Roos HP, Lohmander LS, Ekdahl C, Beynon BD. Knee Injury and Osteoarthritis Outcome Score (KOOS): development of a self-administered outcome measure. *J Orthop Sports Phys Ther*. 1998;28:88-96.
- Stattin EL, Wiklund F, Lindblom K, et al. A missense mutation in the aggrecan C-type lectin domain disrupts extracellular matrix interactions and causes dominant familial osteochondritis dissecans. *Am J Hum Genet*. 2010;86:126-137.
- Uematsu K, Habata T, Hasegawa Y, et al. Osteochondritis dissecans of the knee: long-term results of excision of the osteochondral fragment. *Knee*. 2005;12:205-208.
- Van Demark RE. Osteochondritis dessecans with spontaneous healing. *J Bone Joint Surg Am*. 1952;34:143-148.
- Vasiliadis HS, Danielson B, Ljungberg M, McKeon B, Lindahl A, Peterson L. Autologous chondrocyte implantation in cartilage lesions of the knee: long-term evaluation with magnetic resonance imaging and delayed gadolinium-enhanced magnetic resonance imaging technique. *Am J Sports Med*. 2010;38(5):943-949.
- Ware JE, Snow KK, Kosinski M. *SF-36 Health Survey: Manual & Interpretation Guide*. Boston: The Health Institute; 1997.
- Weckstrom M, Parviainen M, Kiuru MJ, Mattila VM, Pihlajamaki HK. Comparison of bioabsorbable pins and nails in the fixation of adult osteochondritis dissecans fragments of the knee: an outcome of 30 knees. *Am J Sports Med*. 2007;35:1467-1476.
- Zaslav K, Cole B, Brewster R, et al. A prospective study of autologous chondrocyte implantation in patients with failed prior treatment for articular cartilage defect of the knee: results of the Study of the Treatment of Articular Repair (STAR) clinical trial. *Am J Sports Med*. 2009;37:42-55.