

# Expanding Applications of the Subchondroplasty Procedure for the Treatment of Bone Marrow Lesions Observed on Magnetic Resonance Imaging

Jack Farr II, MD,<sup>\*,†</sup> and Steven B. Cohen, MD<sup>‡,§</sup>

Increase in signal on T2-weighted fat-suppressed magnetic resonance imaging is referred to as a bone marrow lesion (BML). Although there is overlap with avascular necrosis, a subset of BMLs is unique and typically associated with overlying chondrosis in a high-load region of the joint. These lesions are often associated with localized knee pain. Several current studies demonstrate improvement in patient-reported outcomes after internally splinting the cancellous bone injuries of the femoral condyles and tibial plateaus with synthetic calcium phosphate bone substitute. As BMLs are often not isolated entities at the tibiofemoral articulation, it follows that the use of the same technique may be applied to the patellofemoral articulation when other pathologies are treated or used in other articulating areas of the knee, specifically the trochlea and patella. This article presents a proposed surgical technique to treat BMLs of these articulating areas.

Oper Tech Sports Med 21:138-143 © 2013 Elsevier Inc. All rights reserved.

**KEYWORDS** subchondroplasty, bone marrow lesion, bone marrow lesions, bone pain

There is increasing consensus that osteoarthritis (OA) should be considered a disease of the whole joint. Historically, there has been a “chicken-egg” debate on the etiology of OA: does cartilage damage lead to bone changes or do primary bone changes lead to articular cartilage degeneration? Most current researchers acknowledge that OA is a multifactorial process involving the articular cartilage, synovium, subchondral bone and bone marrow, menisci, ligaments, and supporting musculature. The degree to which each factor dominates in a particular patient is also multifaceted. Eric Radin was one of the most vocal advocates of the importance of subchondral bone and its relation to pain in OA.<sup>1</sup> His pioneering work explained the interconnected relationship between bone and cartilage. Damage to the

subchondral bone has now been shown to correlate with the presence of pain in knee OA, cartilage destruction, and bone attrition.<sup>2-4</sup>

At homeostasis, the subchondral bone provides support for the overlying articular cartilage and absorbs most of the mechanical force transmitted during joint loading.<sup>1,5</sup> Subchondral bone actively remodels in response to joint loading and focal stress. In the presence of continued stress, or reduced healing ability, the subchondral bone is adversely affected. Scott Dye introduced the concept of “Envelope of Function.”<sup>6</sup> If patients exceed their genetic, morphologic, and/or physiologically determined envelope, then the subchondral bone will demonstrate a stress reaction, often noted first on a bone scan before magnetic resonance imaging (MRI). Over time, the stress reaction becomes MRI positive and histologically identifiable. Histology of the diseased bone reveals a remodeling process that is less well mineralized, shows increased vascularity, and is fibrotic in nature when compared with normal bone.<sup>7-9</sup>

Diseased or overstressed subchondral bone can be seen on fat-suppressed (FS) MRI as a hyperintense white signal commonly referred to as a bone marrow lesion (BML). BMLs are typically seen in the weight-bearing regions of the knee (tibial plateau and femoral condyles) and more commonly on the medial vs lateral compartment.<sup>10</sup> However, BMLs can also

\*Cartilage Restoration Center of Indiana, Greenwood, IN.

†Department of Orthopedic Surgery, The Indiana Orthopedic Hospital, Greenwood, IN.

‡Rothman Institute Orthopaedics, Philadelphia, PA.

§Department of Orthopaedic Surgery, Thomas Jefferson University Hospital, Philadelphia, PA.

Conflict of Interest: Drs Farr and Cohen are both consultants for Knee Creations. Dr Cohen is a developer of the procedure.

Address reprint requests to Jack Farr II, MD, Cartilage Restoration Center of Indiana, 1260 Innovation Parkway, #100, Greenwood, IN 46143. E-mail: indyknee@hotmail.com

be seen in the trochlear region of the femur as well as the patella. Although not recognized (incorrectly) by some as load-bearing surfaces, the patellofemoral compartment has some of the highest loads/stress (force per unit area) of all joints noting that with stair-climbing and jumping, loads can peak at 5-8 times body weight. There are no known differences in structural and chemical changes to the subchondral bone between compressive load-bearing and shear-loading areas of the knee, which both of these forces can show subchondral microdamage that correlates with MRI findings.<sup>11,12</sup> In all cases, classic chronic overload BMLs represent areas of fibrosis, necrosis, and microcracks or microfractures.<sup>13</sup> As BMLs are thought to be a structural and chemical progenitor of OA progression and pain, targeted and timely treatment is an intriguing concept to investigate as 1 tool in the treatment of the pre-OA or established OA patient.<sup>14</sup>

## Proper Imaging

Proper use of MRI is necessary to identify BMLs of the knee. A T2 FS, proton density FS, or short TI inversion recovery image is required to see a BML.<sup>15</sup> Figure 1A demonstrates a BML with proper MRI sequencing, whereas the same lesion is not recognized within Figure 1B when improper sequencing is used. MRI is additionally essential to rule out other sources of intra-articular pain. The typical BML considered for treatment is from focal overload. These vary from stress reaction to frank stress or insufficiency fracture over a continuum. However, at present time, the more global appearance of avascular necrosis is a different entity and recognizing the diverse appearance of the 2 entities may be difficult to discern.

## What is Subchondroplasty?

Subchondroplasty (SBC) (Zimmer Knee Creations; West Chester, PA; a wholly owned subsidiary of Zimmer Holdings, Inc.; Warsaw, IN) is a proprietary term to describe the technique of injecting a flowable calcium phosphate (CaP) synthetic bone-void filler into the space between the trabeculae of cancellous bone in the subchondral region of a

joint—at present, the knee. Earlier forms of injectable CaP used to augment fracture stabilization (eg, radius or vertebral bone) had different flow characteristics that often resulted in compaction or displacement of cancellous bone trabeculae or an open void for implantation. AccuFill, a proprietary CaP (Knee Creations, LLC; West Chester, PA), markedly changes the physical characteristics of pure CaP and allows it to flow between the cancellous trabeculae without damage to the bone structure. Once in position, an endothermic (thus, no heat to kill cells) reaction allows the CaP to crystallize with a porosity and strength that mimics healthy cancellous bone. Over time, osteoclasts or osteoblasts can utilize this scaffold-like implant to remodel local bone.<sup>16</sup>

## Indications

1. Stabilization of focal areas of symptomatic knee subchondral bone marrow lesions.
2. Stabilization of frank bone stress or insufficiency fractures in early phases as demonstrated by bone marrow lesions.

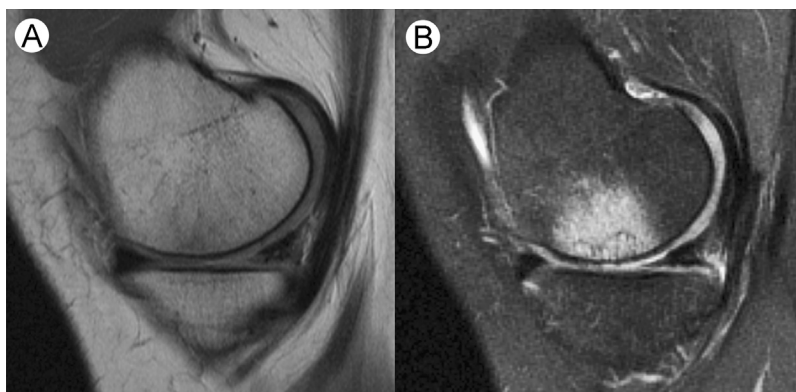A thorough knee examination is always the first step in determining the differential diagnosis of the knee problem. Once the exam, radiographs, and MRI correlate to implicate a BML as contributing to the patient's symptoms, then all other contributing factors are also considered.

## Common Indications

1. Medial tibial plateau
2. Medial femoral condyle
3. Bipolar medial compartment (“kissing” lesion).

## Expanded Indications

1. Lateral femoral condyle
2. Lateral tibial plateau
3. Bipolar lateral compartment



**Figure 1** Example of correct MRI sequencing for bone marrow lesions using fat suppression. BML is not visible on T2 MRI (A) but becomes visible with added fat suppression (B).

4. Patella
5. Trochlea
6. Bipolar patellofemoral compartment
7. Concomitant or staged with meniscectomy, chondral treatment.

## Subchondroplasty Technique

Using the MRI, the extent or volume of the BML should be noted as this will determine the amount of CaP injected. The MRI Osteoarthritis Knee Score (MOAKS) scoring system can be used to quantify the extent of the BML relative to the compartment.<sup>17</sup>

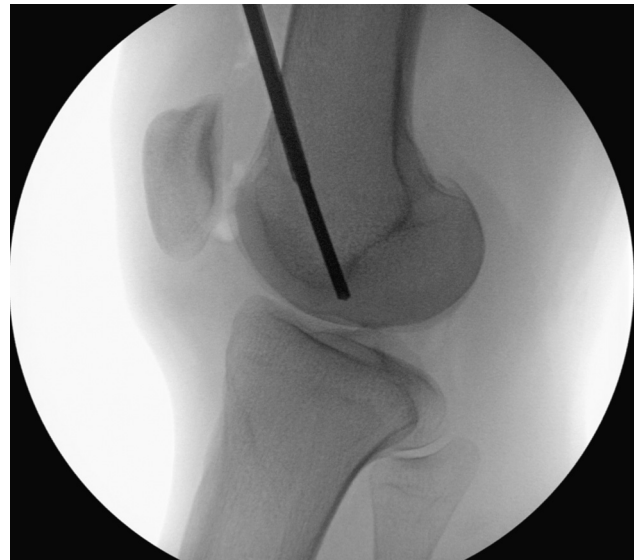The Subchondroplasty procedure is completed with the patient supine with optional thigh tourniquet on a radiolucent operating table. The patient is placed under general, regional, or spinal anesthesia. The operative knee is positioned to allow true anteroposterior (AP) and lateral fluoroscopic views whereas the nonoperative knee is placed flat on the operating table.

In most cases, a diagnostic arthroscopy is performed to assess the intra-articular structures adjacent to the BML. Additional arthroscopic treatments, including debridement chondroplasty, meniscectomy, meniscal repairs, loose body removal, synovectomy, or cyst drainage can be performed at this time. Extra-articular procedures (tibial and femoral osteotomy or tibial tuberosity anteromedialization to decrease stress at the patellofemoral articulation) may also be performed to correct underlying malalignment that may have significantly contributed to the overloaded bone (varus, valgus, and chronic patellar subluxation).

## Treatment of Trochlear and Patella Lesions

The key to short-term success in all cases of Subchondroplasty is to fill the area of BML with the CaP. In patients with lesions that are related to a specific underlying pathology, it is clear that for long-term success the underlying cause of the BML should also be addressed. At the patellofemoral compartment, this is typically from elevated stress or chondrosis.

The importance of obtaining true AP and lateral intraoperative fluoroscopic views cannot be overemphasized. Even with these views, the bony overlap may be confusing. Review of the femoral anatomy and how it relates to the appearance on fluoroscopy is important as the trochlea is only a central segment of the femur as seen on an AP view. On true lateral (with collinear posterior and distal condyle aspects), the trochlear groove is visible as a separate line from the medial and lateral facet margins (Fig. 2). Cross referencing the MRI directly in the operating room in real time is essential. Using triangulation skills learned with arthroscopy a 25-gauge needle may be used to optimize an insertion point typically medial or lateral across from the BML. Once the actual cannula or drill bit is placed in the BML, it is confirmed to be in the correct position on AP, lateral, and oblique views.



**Figure 2** A true lateral fluoroscope image shows the trochlea groove and the medial and lateral facet margins.

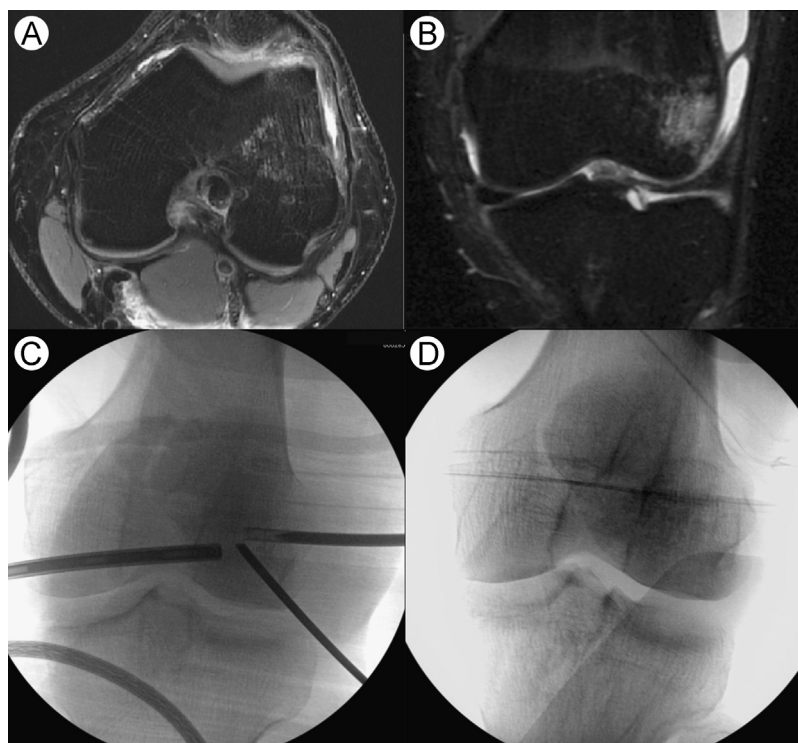
The cannula can then be adjusted to the necessary depth. It is important not to make multiple drill attempts as this can lead to extravasation of the cement. End or side-vented cannulas are selected for optimal uniform dispersion (Fig. 3).

The patella presents with unique problems of movement in full extension. An assistant stabilizing the patella during drilling is useful. The stability may be augmented with use of a large K wire at a distance from the site of injection. Localization is similar to other areas of the knee; a 25-gauge needle may help to select and optimize the approach. Review the Wiberg type of morphology as the depth and position of the median ridge varies. The true lateral view would have 2 parallel lines, the more posterior is the median ridge and the more anterior is the lateral facet margin (Fig. 2). When entering the patella, it is important to remain near the anterior cortex to avoid intra-articular positioning of the cannula. Using the same triangulation skills as for other areas of the joint, the cannula is slowly advanced to the MRI site of the BML and the injection technique mimics the other sites. In this case, typically, the side fenestrations in the cannula are directed posteriorly as the cannula is more anterior as noted earlier (Fig. 4).

Injection of the synthetic bone substitute through the cannula into the area of the BML is performed by applying steady digital pressure until a darkened blush is visible on the fluoroscope that mimics the pattern of the BML on MRI. The cannula may be left in place for 1–3 minutes to allow the bone substitute to cure before removal. Arthroscopic imaging is again used to confirm proper injection of the CaP without extravasation into the joint.

## Complications

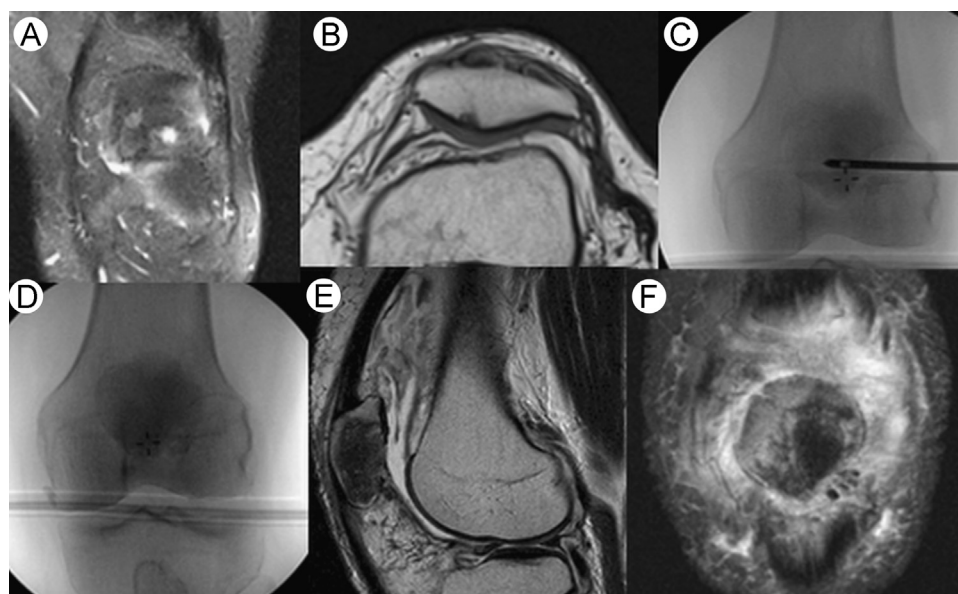
There have been no significant medical complications encountered in the cases performed to date. Extravasation of the bone substitute into the joint of soft tissue is a potential complication. As the CaP is a hydrophilic material, it can be



**Figure 3** BML is located on axial (A) and coronal (B) preoperative MRI. Cannula is inserted proximally, parallel to joint line (C). Intraoperative fluoroscopy images show implanted CaP (D and E).

removed arthroscopically with a standard shaver and lavage during the conclusion of the procedure. There have been no reactions noted from the bone substitute; however, bone substitute that has hardened in the soft tissue can be tender, which has occurred in few patients. This can be minimized by viewing all knee soft tissues fluoroscopically at the end of the procedure.

A subset of patients has reported significant pain postoperatively for up to 72 hours after the surgery, much more intense than the typical knee arthroscopy. Pain management using narcotics or antiinflammatory medications is typically adequate, but at times regional nerve blocks are necessary. In light of this, prolonged postoperative observation is important to be sure that the patient has fully



**Figure 4** BML is located on coronal (A) and axial (B) preoperative MRI. Anteroposterior fluoroscopy guides depth of cannula placement (C). Intraoperative fluoroscopy images show implanted CaP (D). Postoperative MRI shows CaP in bone 3 months postoperation (E and F).

emerged from all anesthetic before release—overnight stay may be necessary in some cases. As such, it is important not to over pressurize the bone substitute upon insertion. Intraosseous pressure measurement in 3 patients revealed normal to slightly elevated baseline pressures following CaP implantation. The pressures transiently increased during the injection, but returned to baseline during the curing phase (Farr personal communication).

The formation of a new BML in previously uninvolved compartment has also been noted. The degenerative nature of the disease may continue to affect other compartments causing newer lesions to develop. Lastly, although not a complication, patients who have failed to obtain significant pain relief have been converted to total knee arthroplasty (TKA) or unicompartmental knee arthroplasty (UKA) without making the index procedure more complicated.

## Postoperative Management

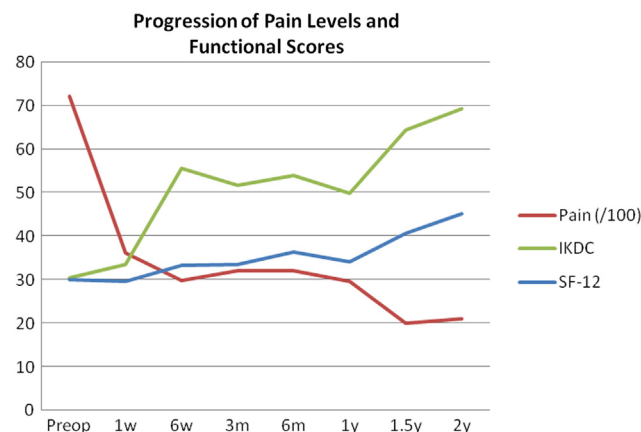
Most patients are discharged the same day or after 23-hours observation with the rare patient requiring hospitalization. It is important to discuss this possibility with patients preoperatively. Narcotics are typically necessary for 24–72 hours following treatment to control postoperative pain. Patients are evaluated approximately 7–10 days postoperatively to remove sutures and assess surgical healing. Patients are recommended to maintain weight-bearing as tolerated with crutches for 1–2 weeks. Formal physical therapy is initiated within 2 weeks of the surgery and typically lasts for 4–8 weeks after surgery. Significant pain reduction and return to full activity may take up to 2–3 months from the time of the surgery.

## Preliminary Results

Fifty-nine patients underwent SBC at 1 author's institution from November 2008 to January 2012. This included 29 females and 30 males with an average age of 55.6 years (range: 35–76 years) and an average body mass index of 30.3 kg/m<sup>2</sup>. Patients were suffering from knee pain for a mean period of 22.5 weeks before they underwent subchondroplasty surgery. Mean preoperative range of motion was 123.5° (range 100°–135°) with 13.6% of patients presenting a flexion contracture of 5 degrees or more. Average alignment was 1.8° of clinical varus (range: 10° varus–8° valgus).

Based on preoperative MRIs, 37.3% of patients had a tibial BML, 25.4% had a femoral BML, and 37.3% had BML in both bones (kissing lesions). Furthermore, 81.4% of patients had involvement of the medial compartment(s), 13.6% had involvement of the lateral compartment(s), and 5.1% had involvement of both medial and lateral compartments.

Mean follow-up was 14.7 months with 83.1% of patients having more than 6 months of follow-up and 66.1% having over a year of follow-up. Fifteen patients (25%) had continued pain and elected to undergo reconstructive surgery after a mean period of 10.1 months after subchondroplasty (range:



**Figure 5** Progression of pain and functional scores during specific time intervals postoperatively. (Color version of figure is available online.)

4.2–22 months). Eleven patients underwent TKA, whereas 4 underwent UKA.

In patients with over 6 months of follow-up who retained their native knee, pain, International Knee Documentation Committee (IKDC), and SF-12 scores significantly improved from preoperative values of 7.5, 30.6, and 29.8 to 3.1, 53.0, and 36.7, respectively, at latest follow-up ( $P$ -values < 0.001). **Figure 5** represents the progression of these scores at the different postoperative visits. Mixed model statistics were used to assess the significance of these changes and all 3 models yielded  $P$ -values of less than  $1E^{-7}$ . Pain scores seem to witness a brisk improvement in the immediate postoperative period with a less pronounced but still progressive improvement afterwards. However, functional scores display a more progressive improvement over time with each follow-up visit.

We failed to identify any significant predictors of failure, as age, gender, body mass index, length of symptoms, preoperative knee alignment, preoperative range of motion, preoperative flexion contracture, prior knee arthroscopy, and preoperative and early postoperative pain and functional scores were not statistically significant between the groups of patients who were converted to TKA or UKA.

## Conclusion

BMLs are increasingly recognized now that there is a potential treatment. Originally described for use in patients with degenerative joint disease, Subchondroplasty is now being expanded to younger patients without frank arthrosis and to other areas of the knee. As with all new applications, the final role for Subchondroplasty will be dependent upon the outcomes of ongoing prospective studies.<sup>18</sup>

## Acknowledgments

The authors would like to thank Andi Clifford, LAT, ATC at OrthoIndy for proofing and organizing this article and Meenal Lele at Knee Creations for gathering background information.



## References

1. Radin EL, Rose RM: Role of subchondral bone in the initiation and progression of cartilage damage. *Clin Orthop Relat Res*:34–40, 1986
2. Felson DT, Chaisson CE, Hill CL, et al: The association of bone marrow lesions with pain in knee osteoarthritis. *Ann Intern Med* 134:541–549, 2001
3. Wluka AE, Wang Y, Davies-Tuck M, et al: Bone marrow lesions predict progression of cartilage defects and loss of cartilage volume in healthy middle-aged adults without knee pain over 2 yrs. *Rheumatology (Oxford)* 47:1392–1396, 2008
4. Roemer FW, Neogi T, Nevitt MC, et al: Subchondral bone marrow lesions are highly associated with, and predict subchondral bone attrition longitudinally: The MOST study. *Osteoarthritis Cartilage* 18:47–53, 2010
5. Madry H, van Dijk CN, Mueller-Gerbl M: The basic science of the subchondral bone. *Knee Surg Sports Traumatol Arthrosc* 18:419–433, 2010
6. Dye SF: The knee as a biologic transmission with an envelope of function: A theory. *Clin Orthop Relat Res*:10–18, 1996
7. Hunter DJ, Gerstenfeld L, Bishop G, et al: Bone marrow lesions from osteoarthritis knees are characterized by sclerotic bone that is less well mineralized. *Arthritis Res Ther* 11:R11, 2009
8. Walsh DA, McWilliams DF, Turley MJ, et al: Angiogenesis and nerve growth factor at the osteochondral junction in rheumatoid arthritis and osteoarthritis. *Rheumatology (Oxford)* 49:1852–1861, 2010
9. Taljanovic MS, Graham AR, Benjamin JB, et al: Bone marrow edema pattern in advanced hip osteoarthritis: quantitative assessment with magnetic resonance imaging and correlation with clinical examination, radiographic findings, and histopathology. *Skeletal Radiol* 37:423–431, 2008
10. Sowers M, Karvonen-Gutierrez CA, Jacobson JA, et al: Associations of anatomical measures from MRI with radiographically defined knee osteoarthritis score, pain, and physical functioning. *J Bone Joint Surg Am* 93:241–251, 2011
11. Nagaraja S, Couse TL, Guldberg RE: Trabecular bone microdamage and microstructural stresses under uniaxial compression. *J Biomech* 38:707–716, 2005
12. Eriksen EF, Ringe JD: Bone marrow lesions: A universal bone response to injury? *Rheumatol Int* 32:575–584, 2012
13. Zanetti M, Bruder E, Romero J, et al: Bone marrow edema pattern in osteoarthritic knees: Correlation between MR imaging and histologic findings. *Radiology* 215:835–840, 2000
14. Lories RJ, Luyten FP: The bone-cartilage unit in osteoarthritis. *Nat Rev Rheumatol* 7:43–49, 2011
15. Hartley KG, Damon BM, Patterson GT, et al: MRI techniques: A review and update for the orthopaedic surgeon. *J Am Acad Orthop Surg* 20:775–787, 2012
16. Welch RD, Zhang H, Bronson DG: Experimental tibial plateau fractures augmented with calcium phosphate cement or autologous bone graft. *J Bone Joint Surg Am* 85-A:222–231, 2003
17. Hunter DJ, Guermazi A, Lo GH, et al: Evolution of semi-quantitative whole joint assessment of knee OA: MOAKS (MRI Osteoarthritis Knee Score). *Osteoarthritis Cartilage* 19:990–1002, 2011
18. Sharkey PF, Cohen SB, Leinberry CF, et al: Subchondral bone marrow lesions associated with knee osteoarthritis. *Am J Orthop* 41:413–417, 2012