



ELSEVIER

Tibial Tuberosity Osteotomies

Jack Farr, MD*, and Brian J. Cole, MD, MBA†

Historically, the tibial tuberosity (also referred to as the tibial "tubercle") was moved empirically to affect force vectors acting at the patellofemoral (PF) compartment of the knee. Maquet moved the tuberosity anteriorly to theoretically decrease PF forces in an effort to manage PF pain associated with arthritis. The techniques of Elmslie and Trillat moved the tuberosity medially to decrease the lateral force vectors to treat episodic or recurrent lateral patellar instability. Currently, tibial tuberosity osteotomies have more narrowed indications, which are directed at normalizing tuberosity position and optimizing PF forces. The extent of anteriorization and medialization are increasing on the basis of objective imaging and laboratory biomechanical force and contact data. With this new attempt to objectify the extent of anteriorization and medialization, the goal is to improve both short- and long-term clinical outcomes.

Oper Tech Sports Med 18:107-114 © 2010 Published by Elsevier Inc.

KEYWORDS anteromedialization, medialization, osteotomy, patella, tibial tubercle

Tibial tuberosity osteotomies have a long and somewhat checkered history. The Maquet¹ tibial tuberosity straight anteriorization (TTSA) technique was designed to decrease loads in an arthritic patellofemoral (PF) compartment. Although the Maquet procedure was often successful at reducing pain, problems surfaced as some surgeons expanded the indications to generalized and ill-defined PF pain and there were intermittent reports of skin necrosis, loss of tuberosity elevation, and fracture.² The Hauser medialization technique included a component of posteriorization that led to medial PF arthritis.^{3,4} The Elmslie-Trillat straight medialization (TTSM) technique was often used in isolation to treat recurrent lateral patellar instability before the medial patellofemoral ligament (MPFL) was recognized as the essential restraint in preventing lateral patellar instability.⁵⁻⁷ Kuroda et al^{8,9} demonstrated the potential harmful biomechanical consequences of overmedialization of the tibial tuberosity as the effect is overloading not only the medial PF compartment, but also the medial tibiofemoral compartment. Fulkerson¹⁰ combined the positive attributes of anteriorization and me-

dialization through his anteromedialization (AMZ) technique. Initially, AMZ was used empirically to treat PF pain with chondrosis and/or patellar instability. In a review of prior AMZ cases, Pidioriano et al¹² noted optimal patient outcomes occurred when the patient had distal lateral patellar chondrosis, and poor results occurred with medial, panpatellar, proximal poles chondrosis or whenever the trochlea was also involved.¹¹ The addition of PF cartilage restoration markedly improved the outcomes of PF chondrosis cases, especially those that would have been expected to have poor results with AMZ alone.¹²⁻¹⁶ By contrast, failure to address PF malalignment during cartilage restoration was associated with poor results. With the European description of an objective measurement of the tuberosity position (tibial tuberosity to trochlear groove [TT-TG] distance), it was then possible to attempt to objectively plan the extent of medialization. Since the mathematical calculation of Maquet, numerous authors have used direct PF force and contact area measurements to suggest optimal anteriorization.¹⁷ Using historical outcomes, current imaging, and laboratory data, it is hoped that more rigid indications may be developed for tibial tuberosity surgery in an effort to further improve patient care.

Indications

There are 5 basic clinically relevant tibial tuberosity translations (medial, anterior, proximal, distal, and lateral) and 2 combined displacements (AMZ and anterolateralization), noting that moving the tuberosity posteriorly is contraindi-

*Cartilage Restoration Center of Indiana, OrthoIndy Knee Care Institute, Indiana University School of Medicine, Indianapolis, IN.

†Departments of Orthopedics & Anatomy and Cell Biology, Division of Sports Medicine, Cartilage Restoration Center at Rush, Rush University Medical Center, Chicago, IL.

Dr Farr was a design surgeon for 2 tibial tuberosity jigs: 1 by Mitek and 1 by Arthrex (Consultation fees and royalties).

Address reprint requests to Jack Farr, MD, OrthoIndy Knee Care Institute, 5255 East Stop 11 Rd, Suite 300, Indianapolis, IN 46237. E-mail: indyknee@hotmail.com

cated as it would increase the load to the patella. In the past, the extent of tuberosity movement was empirical, and in some cases there was the potential for the tuberosity movement to cause overmedialization. In addition, the medialization procedures were used in cases where the essential medial PF ligament was not appreciated.^{16,18} The following indications are a "work in progress" as the surgeon, therapist, and scientific PF community attempt to refine indications on the basis of clinical outcomes, objective imaging measurements, and laboratory findings. Before assuming that a specific amount of tibial tuberosity movement will have a specific effect on PF stress, the analytical work of Ateshian should be reviewed. This study demonstrated that the potential biomechanical effects of anteriorization and medialization are highly variable from knee to knee (noting that the TT-TG measurement was not used at the time of this study to decide on the extent of medialization as is now suggested).¹⁹

Medialization

Although TTSM does decrease the lateral component of the quadriceps vector, its current use in patients with recurrent lateral patellar instability is controversial because isolated MPFL reconstruction without tuberosity medialization has a high success rate. If considered as an adjunct to MPFL repair or reconstruction (to decrease the forces acting on the repair or reconstruction), the extent of medialization would be calculated by using the TT-TG distance. If it is definitely abnormal (>20 mm), then the goal would be to normalize to a distance that is the mean of patients without PF symptoms or instability (13 mm).^{19,20} Certainly, the isolated use of TTSM is rarely indicated because those patients with chondrosis and chronic subluxation benefit from the decrease loads of AMZ and those patients with symptomatic static chronic patellar subluxation of the patella are rare. In these cases, the TT-TG would be normalized. Obviously, if the TT-TG is within normal limits, there is no indication for medialization. Only a randomized prospective comparison of MPFL surgery with and without TTSM will allow a final recommendation.

Anteriorization

Various authors using a variety of laboratory testing techniques have suggested a range of desired anteriorization distances. Reviewing the published data, it appears that PF stresses can be decreased in the range of 20%, with an anteriorization between 10 and 15 mm, without causing excessive sagittal plane patellar rotation or resultant altered contact areas. The decision to perform a TTSA is based on the goal of decreasing load to an area of PF chondrosis, which has been determined (by exclusion) to be the main contributor of PF pain. Currently, this is typically combined with a PF cartilage restoration procedure. However, the decrease in PF stress is only in the range of 20% and TTSA is not without morbidity. A case can be made that when PF cartilage restoration is performed in addition to a TTSA, it is easier for the patients to restrict themselves to level ground walking where PF forces are in the range of 0.5 body weight until the cartilage con-

struct has healed and can accept higher loads. TTSA is not indicated for anterior knee pain of ill-defined origin.

Anteromedialization

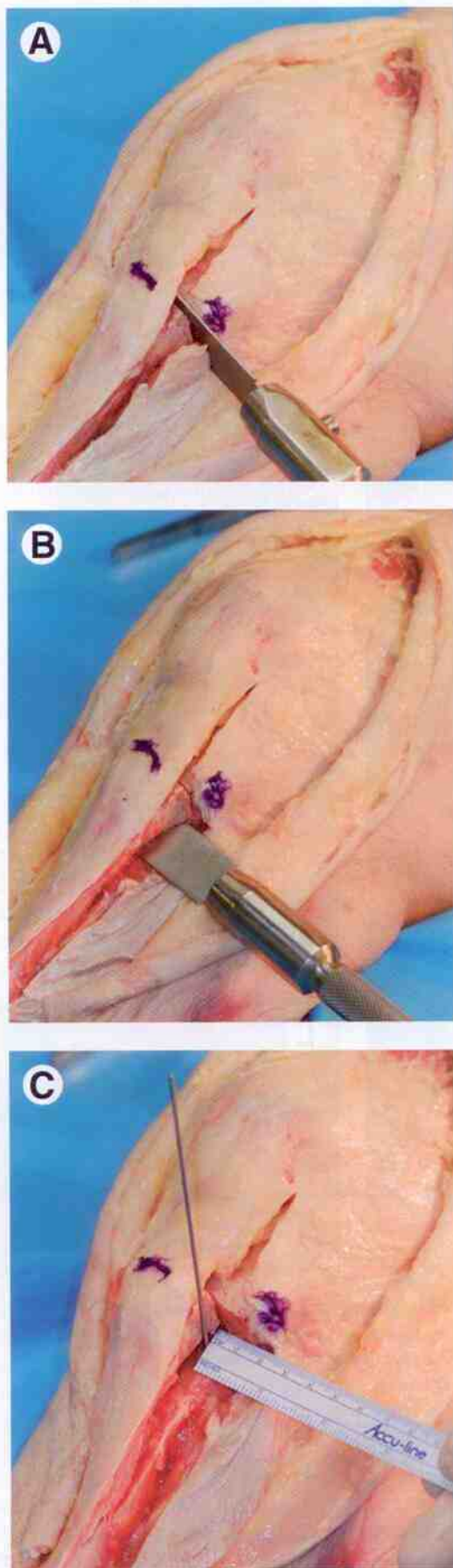
Isolated AMZ is primarily indicated in patients with isolated distal lateral or distal patellar chondrosis (intact trochlea) that have an elevated TT-TG distance. It is also indicated in patients undergoing PF cartilage restoration who have elevated TT-TG distances. It is contraindicated as an isolated procedure for patients with proximal pole, medial, panpatellar, trochlear, or bipolar chondrosis, yet would be added to these cases when cartilage restoration is performed and the TT-TG was abnormally elevated.

Distalization

There has been some hesitancy in the United States to perform tibial tuberosity distalization for fear of creating patellar infera or increasing PF loads. Patella infera, however, is typically a biological scarring response to trauma or surgery and is not a sequel of tibial tuberosity distalization, if the distalization normalizes the patellar height. PF forces are abnormally high in patella alta and are normalized as the patellar position is normalized through distalization.²⁰⁻²³ As the Insall-Salvati measurement of patellar height references the tuberosity, it would not change with distalization of the tuberosity. Therefore, it is preferable to use a reference to the anterior proximal tibia, such as the Caton-Deschamps (CD) ratio (normal range, 0.8-1.2), noting the distance of the tuberosity to the joint line is a relative constant. The extent of alta can also be measured comparing the inferior extent of the subchondral region of the patella to the proximal extent of the trochlea. If there is disagreement in assessing the CD and patella to trochlear entrance measurements, this would suggest a short trochlea, which would contraindicate distalization. Indications for distalization are most common in patients with patellar instability with an elevated CD ratio and normal TT-TG. The extent of distalization is calculated by correcting for radiographic magnification and then subtracting the subchondral height of the patella from the distance of the anterior proximal tibia to the inferior point of the subchondral extent of the patella. After bony distalization, the excessive tendon length would remain, and thus Neyret²⁴ has suggested tenodesis of the patellar tendon to the original proximal site of patellar tendon attachment to the tibial tuberosity. His rationale is to avoid hypermobility of the tendon (windshield wiper effect), but this awaits a prospective comparative study. In the case of PF chondrosis, distalization can be combined with TTSA or AMZ to further optimize PF stress. Obviously, distalization is contraindicated if the CD ratio is normal.

Proximalization

An excessively distal patella is from patella tendon and soft-tissue shortening as a biological response to trauma, which includes surgical trauma. That is, it is not the result of the tuberosity position being excessively distal to the tibial joint line. The treatment of patella infera is complex and multifac-



torial and outside the context of this article. Nevertheless, if all other techniques are optimized, then minor amounts of proximalization at the level of the tibial tuberosity may be an option. One must take care not to impinge on the tibial joint line, which could complicate future surgeries. A degree of "skeletonization" of the proximal tuberosity and removal of this exposed bone can allow several millimeters of proximalization without the ill-effect of proximalizing the patellar tendon attachment. This technique may also be combined with AMZ. Proximalization is contraindicated if the patella position is normal.

Lateralization

As the tibial tuberosity is naturally lateral to the midline of the trochlear groove, the only indication for lateralization of the tibial tuberosity is after overzealous surgical medialization. The goal would be to normalize the tuberosity position. In the case of a prior Hauser procedure, which has a component of posteriorization, the tuberosity would be anterolateralized as described by Fulkerson.

Surgical Technique

Medialization

Straight medialization may be performed through a longitudinal incision lateral to the tibial tuberosity, which avoids the patient kneeling on a skin scar. The medial and lateral aspects of the patellar tendon are incised longitudinally to allow displacement of the tuberosity pedicle. The decision to perform a lateral release or lateral lengthening is made on the basis of mobility of the lateral retinaculum and may be performed open or arthroscopically. The lateral incision along the patellar tendon continues along the lateral aspect of the tibial tuberosity in line with the lateral attachment site of the patellar tendon and separates the anterior aspect of the anterior compartment musculature from the extension of the patellar tendon attachment to the tuberosity. The anterior compartment muscular is elevated and retracted 1.5 cm posteriorly. The patellar tendon is protected as the proximal lateral to medial cut (in the axial plane) is made immediately proximal to the patellar tendon attachment at the tibial tuberosity (Fig. 1A). The second cut is made in the coronal plane 1.5 cm posterior to the tuberosity crest using a wide osteotome (Fig. 1B). The osteotomy is directed lateral to medial parallel to the posterior plane of the knee (flat cut or erring slightly anteromedial). The osteotome is turned distally to create a tuberosity pedicle that is free proximally, medially, and laterally, but remains intact distally. If the pedicle is too thin, it may fracture or fail to unite, and if too thick, it may be very difficult to

Figure 1 (A) Patellar tendon is protected and anterior compartment musculature elevated before axial plane cut proximal to patellar tendon attachment to tibial tuberosity. (B) Coronal plane cut, which leaves the distal bone intact. (C) After osteoclasia of the tibial tuberosity, pedicle is rotated medially as preoperatively determined by the tibial tuberosity to trochlear groove (TT-TG) distance.

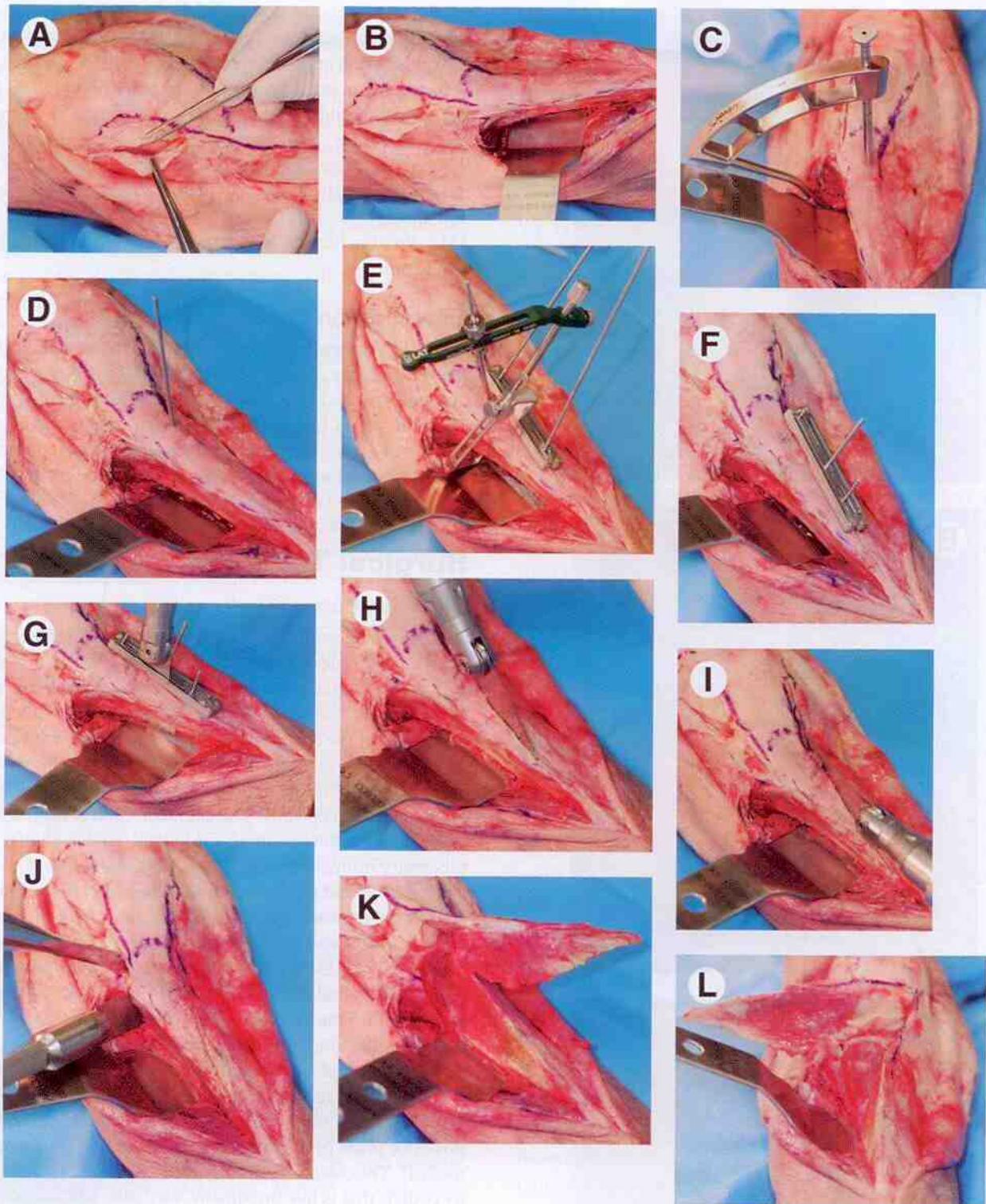


Figure 2 (A) Steep cut between the superficial oblique and deep transverse fibers of the lateral retinaculum will allow lateral lengthening at closure. (B) Anterior compartment musculature is elevated from the lateral wall of the tibia with retractor protecting anterior tibial artery and deep peroneal nerve. (C) Jig referencing posterior wall of proximal tibia allows insertion of reference pin perpendicular to posterior wall. (D) Reference pin is perpendicular to posterior wall. (E) Desired slope is determined preoperatively, and intraoperatively that jig is attached to the vertical reference pin, which aligns the cutting block. (F) Cutting block is secured. (G) Oscillating saw cooled with saline creates the initial sloped osteotomy, exiting on the protective retractor. (H, I) After the cut is completed through the cutting block that block is removed and the osteotomy is used as a "captured saw guide" to complete the proximal and distal extents of the sloped osteotomy. (J) Proximal cuts are completed with osteotomes directed at 2 different angles. (K, L) After the proximal cuts, the tibial tuberosity pedicle is free. (M, N) The distance of medialization and anterization is measured directly and the pedicle is secured with 2-4.5-mm screws with interfragmentary technique.

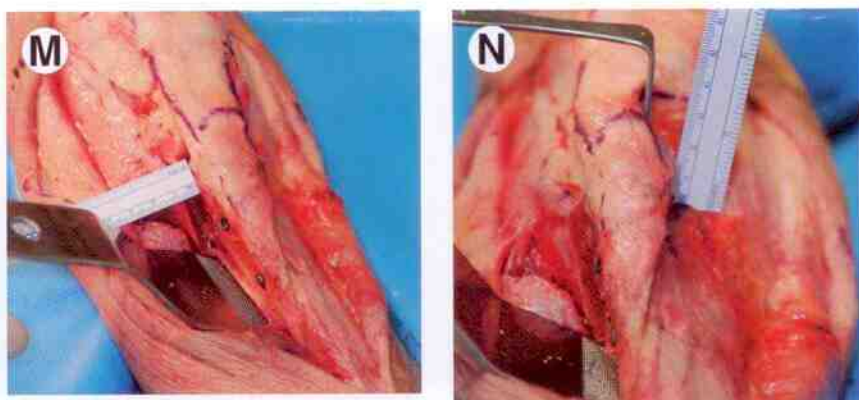


Figure 2 (Continued)

perform an osteoclast and achieve the desired rotation. To create the distal green stick fracture, an osteotome within the flat cut may be rotated in the sagittal plane to temporarily elevate the pedicle. After the osteoclast, the tuberosity pedicle is repositioned in its bed and medialized. The amount of medialization is directly measured to ensure a normalization of the TT-TG (Fig. 1C). Often the medial proximal corner of the pedicle is sharp and is trimmed with a rongeur. The pedicle is fixed with two 4.5-mm screws using the standard lag technique to compress the osteotomy site.

Anteriorization

Straight anteriorization may be performed in the classic Maquet manner, but to decrease skin complications and the need for iliac crest harvest 1 of 2 Fulkerson techniques may be used. The first involves performing a standard, very steep AMZ cut, and then placing locally obtained cancellous bone to offset the medialization component.²⁵ The second technique is performed free-hand. The first tuberosity cut is a straight anterior to posterior in the sagittal plane in line with the medial border of the patellar tendon. Extreme caution is necessary to avoid penetrating the posterior cortex. A second cut is made in the coronal plane 5-10-mm anterior to the posterior wall of the tibia. Proximally, the cuts are the same as for AMZ (see later). Two 4.5-mm lateral to medial interfragmentary screws fix the pedicle after anteriorization.

Anteromedialization

The Fulkerson²⁶ concept of using a guide for the creation of the sloped cut is widely accepted. Fulkerson initially used an external fixator drill pin guide. To allow better prediction of the posterior exit of the osteotomy, he then used a commercial guide (Tracker, DePuy Mitek, Raynham, NJ) that is well described and illustrated in unpublished data.¹⁶ Therefore, emphasis will be placed on a new guide system for AMZ (T3, Arthrex, Naples, FL). Whether the cuts are made freehand or using a guide, the first steps are the same. Lateral tilt is common in patients undergoing AMZ, so proximally the lateral retinaculum may undergo a lateral release or lateral lengthening to allow reversal of tilt. Lateral lengthening involves incising the oblique component of the lateral retinaculum at the patella and elevating from the deep transverse compo-

ment, which is then incised 1.5 cm posterior to the patella (Fig. 2A). This will not only allow closing the joint at the end of the procedure, but will also maintain definitive lateral control with precise lengthening. Longitudinal incisions are made adjacent to the patellar tendon. The lateral incision is continued along the lateral margin of the tibial tuberosity. This allows subperiosteal elevation of the anterior compartment musculature exposing the lateral wall of the tibia. A retractor is placed adjacent to the posterior wall to maintain the exposure and protect the anterior tibial artery and the deep peroneal nerve (Fig. 2B).

For the T3 guide system, a reference pin is placed anteriorly perpendicular to the posterior wall of the tibia at the level of the proximal extent of the tibial tuberosity (Figs. 2C and D). The desired slope is selected on the basis of preoperative measurements and desired amount of medialization and anteriorization. For a specific slope, a slope guide is attached to the reference pin. The saw guide block is positioned immediately adjacent to the medial patellar tendon attachment to the tibial tuberosity and is angled laterally distally to allow the osteotomy to exit distally. The osteotomy exit is confirmed (Fig. 2E). After confirmation of the osteotomy angle, entrance, and exit sites, the saw guide is secured (Fig. 2F). After the cutting block is secured, all the classic steps detailed by Fulkerson using the Tracker AMZ guide are similar. The slope cut is made through the cutting block (Fig. 2G). The cutting block is removed and the osteotomy cut is used as a captured guide to complete the proximal and distal extents of the sloped cut (Figs. 2H and I). The osteotomy is completed proximally with 1 osteotome path coursing from the posterior proximal extent of the sloped cut to immediately adjacent to the lateral attachment of the patellar tendon and the final cut is lateral to medial just proximal to the patellar tendon attachment to the tibial tuberosity (Fig. 2J). The tibial tuberosity pedicle is now free to allow AMZ of the pedicle "up" the slope of the osteotomy (Figs. 2J and K). After the planned anteriorization and medialization are achieved, the pedicle is fixed with 2 lag screws perpendicular to the osteotomy, which directs them away from neurovascular tissues. The amount of anteriorization and medialization are measured directly (Figs. 2M and N).

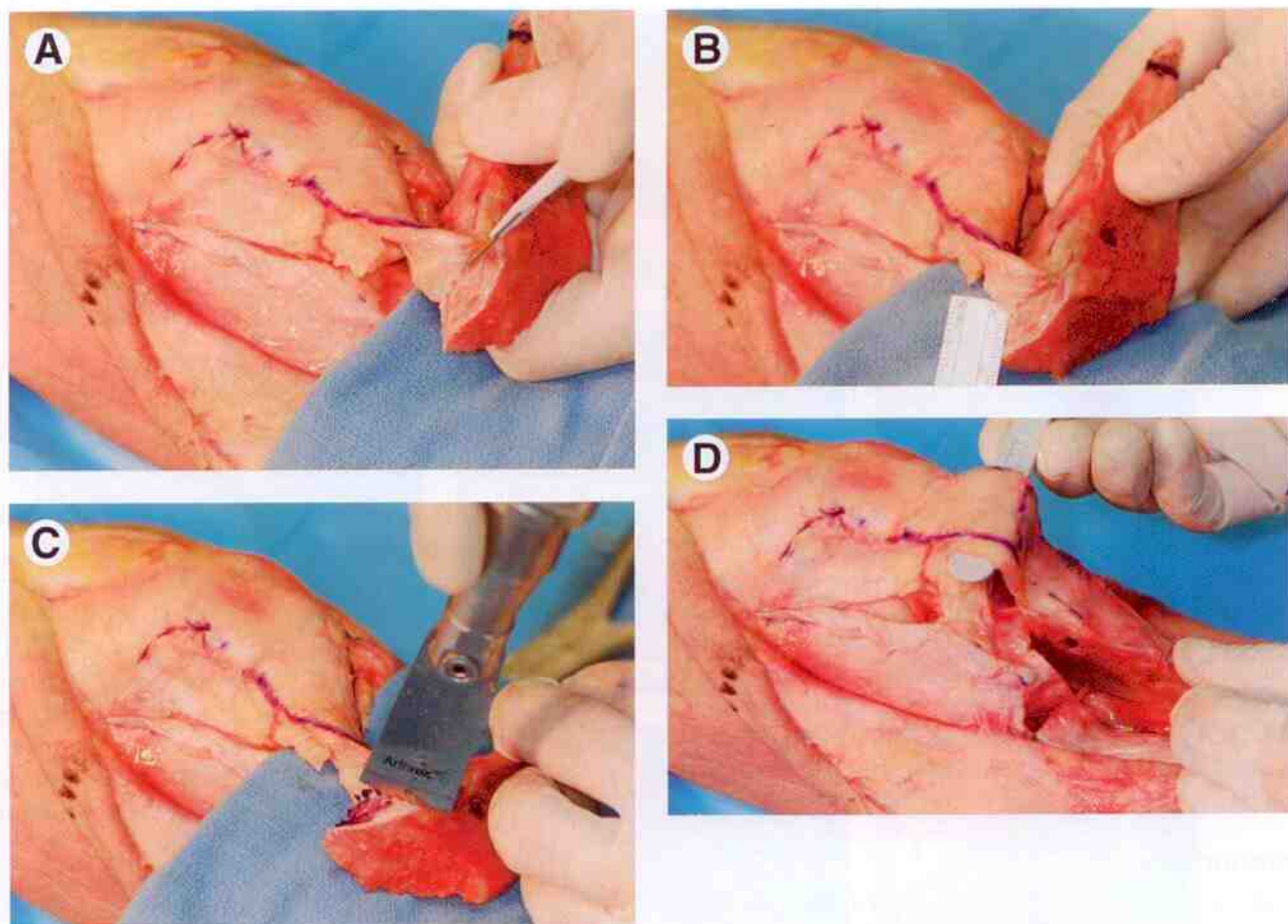


Figure 3 (A) The patellar tendon is sharply elevated from the proximal attachment to the tibial tuberosity. (B) The elevation (skeletonization) of the patellar tendon may allow a maximum of 1.5 cm of proximalization. (C) To proximalize the patella/ patellar tendon without proximalization of the tendon attachment site, the skeletonized bone is removed. (D) The tibial tuberosity is proximalized to the original attachment site allowing lengthening of the patellar tendon without alteration of the attachment site.

Proximalization

Proximalization is performed when the patella is too distal, and all other components of arthrofibrosis and/or patella infera have been resolved. Moving the tuberosity alone would place it closer to the joint line and potentially adversely affect future surgical intervention. As the patella tendon attaches for considerable length on the tibial tuberosity, it is possible to skeletonize the proximal tuberosity for up to 1.5 cm (Figs. 3A and B). The skeletonized proximal bone is removed (Fig. 3C). The new patellar tendon attachment site on the new tuberosity is then proximalized in the original bed allowing lengthening of the patellar tendon without proximalizing the attachment site (Fig. 3D). The pedicle fixation is performed by standard interfragmentary screws.

Distalization

As the patellar tendon will follow the tuberosity distally, the medial and lateral margins of the patellar tendon are incised to allow the transfer, and these incisions are continued distally onto the tibial tuberosity for 8-10 cm. A saw is used to

make medial and lateral longitudinal cuts in tuberosity, which are angled to allow a good base of cancellous bone for healing (Fig. 4A). The amount of distalization is determined preoperatively from lateral radiographs corrected for magnification. Typical amounts of distalization are 8-10 mm. That amount of bone is removed and the tuberosity is positioned in the distal aspect of the tuberosity bed (Figs. 4B and 4C). The patellar tendon remains longer than normal, even with the patella now in a normal position. If there is a desire to normalize the patellar tendon length, it may be tenodesed using suture anchors and the original proximal attachment site (Figs. 4D and E).

Lateralization

Lateralization is performed after and excessive TTSM and therefore uses the original planes. The extent of lateralization is determined preoperatively using the TT-TG distance.

Anterolateralization

If there is significant chondrosis, a component of anteriorization may be added. This is a mirror image of the AMZ

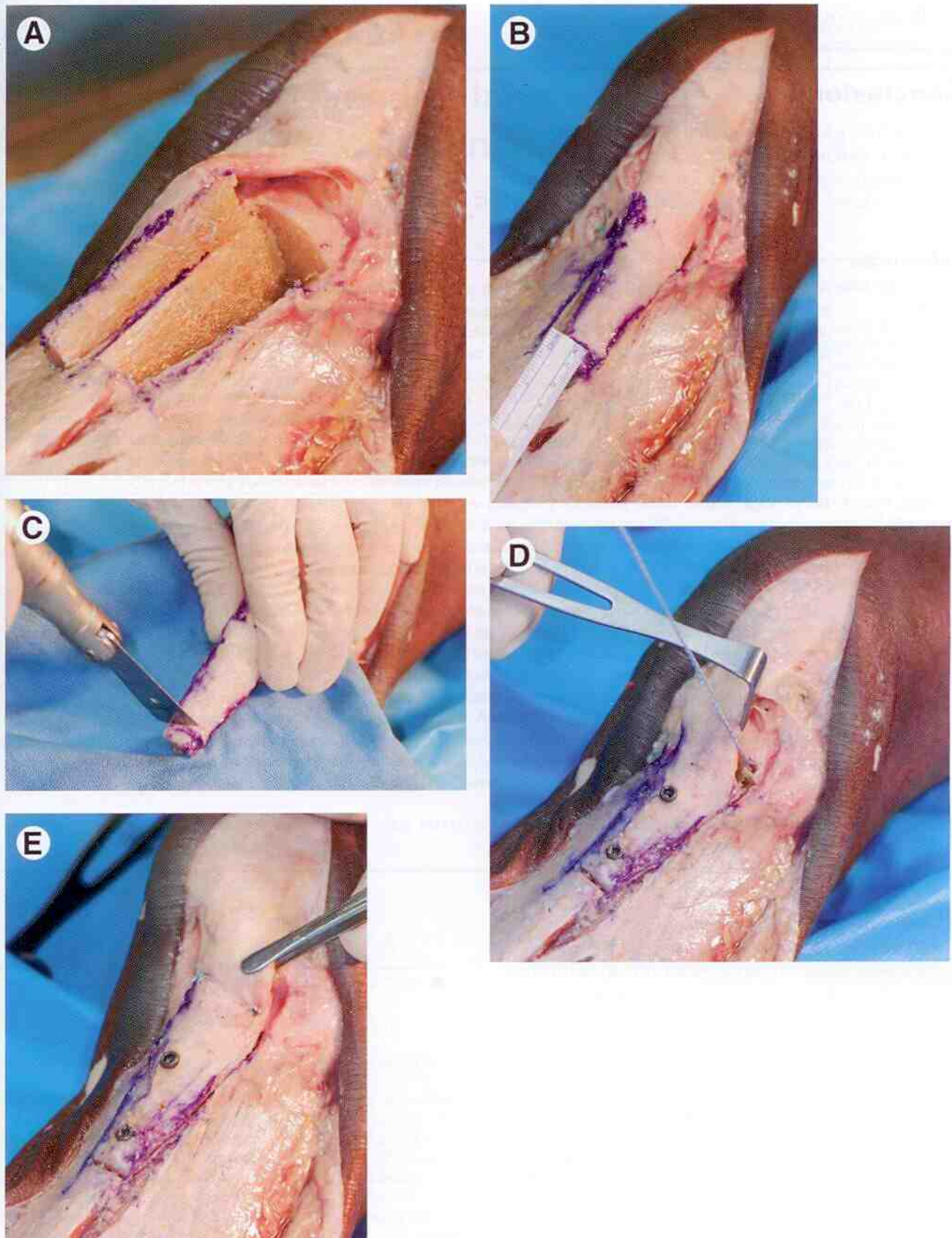


Figure 4 (A) Tuberosity and medial and lateral aspects of patellar tendon freed. (B) Distal cut is measured based on preoperative measurements from magnification corrected radiographs. (C) Distal cut made with saw. (D) Tibial tuberosity is distalized and fixed with 2 4.5 mm screws. Option of tenodesing the tendon at the original attachment site. (E) Tenodesis of patellar tendon at the original attachment site with 2 suture anchors.

