

Effect of Patellar Taping and Bracing on Patellar Position: An MRI Case Study

Teddy W. Worrell, Christopher D. Ingersoll, and Jack Farr

The purpose of this case study was to determine the effect of patellar taping, patellar bracing, and control condition on (a) patellofemoral congruence angle (PFC), (b) lateral patellar angle (LPA), (c) lateral patellar displacement (LPD), and (d) pain, as determined by the visual analog scale (VAS) during an 8-in. step-down. The subject was a 15-year-old female with a 3-year history of recurrent patellar subluxations and anterior knee pain syndrome. Results revealed the following: control condition—PFC 41.4–1.1°, LPA 19.9–6.9°, LPD 18.6–8.3 mm, VAS 8.8 cm; tape—PFC 46.2–2.3°, LPA 25.1–2.9°, LPD 24.2–7.5 mm, VAS 0.8 cm; brace—PFC 3.4–16.5°, LPA 7.9–0.8°, LPD 9.4–4.7 mm, VAS 0.3 cm. Patellar bracing was effective in centralizing the patella as revealed by the PFC, LPA, and LPD measures; however, patellar taping did not improve patellar position, and in some positions taping actually worsened patellar position. A large reduction in pain as measured by the VAS occurred during an 8-in. step-down for both taping and bracing. More research is necessary to explain the pain reduction without a change in patellar position using tape.

Patients with patellar pain are frequently referred for rehabilitation. Rehabilitative protocols are prescribed under the assumption that they will reduce symptoms and improve patellar alignment. Rehabilitation generally consists of specific exercises to recruit the vastus medialis oblique (VMO) (6), general quadriceps exercises, and stretching of tight lateral structures (2). In addition, patellar taping (McConnell) and bracing (Palumbo) have been suggested for the treatment of patellar pain (4, 5).

Recently, patellar position measurements have been used to evaluate the effectiveness of conservative treatments for changing patellar tracking (1–3). These studies have evaluated the effects of taping (1), progressive resistive exercises and EMG biofeedback (3), and exercise and stretching (2) on patellar

Teddy W. Worrell is with the University of Indianapolis Krannert School of Physical Therapy, 1400 E. Hanna Ave., Indianapolis, IN 46227. Christopher D. Ingersoll is with Indiana State University Department of Athletic Training, Terra Haute, IN 47809. Jack Farr is with Specialty Centers for Orthopaedic and Rehabilitative Excellence, Indianapolis, IN 46227.

position using a standard or modified Merchant's view radiograph. This view of the patella provides valuable information but has limited applications, because the Merchant's view uses a 45° knee angle and the patella has already engaged in the patellofemoral groove. Consequently, the position of the patella at other points within the range of motion is not known. Therefore, the contribution of the quadriceps and other soft tissues in determining patellar position is reduced.

Patellar taping and bracing studies have claimed to correct patellar tracking (4, 5). These studies have measured decreased pain and improved function. They have not, however, quantified changes in patellar position or tracking, although resolution of symptoms in these studies has been attributed to changes in patellar tracking. One study that evaluated the effects of patellar taping on patellar position at 45° of knee flexion reported no significant change of patellar position after taping (1).

In order to better understand patellar position throughout knee range of motion following patellar taping and bracing, it is necessary to measure patellar position at various knee angles. Therefore, the purpose of this case report was to use magnetic resonance imaging (MRI) to compare measurements of patellar position using the patellofemoral congruence angle (PFC), lateral patellar angle (LPA), and lateral patellar displacement (LPD) at eight knee angles following patellar taping, patellar bracing, and a control condition.

Methods

Subject

A 15-year-old female participated in this study. Prior to participation, her mother signed a release form. This patient had sustained a left patellar dislocation with spontaneous reduction 3 years previously while performing gymnastics. Since that time she had reported four or five left patellar subluxations. After each episode, she experienced swelling and pain. Subsequently, she developed left anterior knee pain with activities of daily living, especially ascending and descending stairs. Her last patellar subluxation occurred when she "turned the wrong way." In addition, she reported one occasion in which her right patella dislocated and spontaneously reduced.

Anterior–posterior and lateral X rays revealed almost full closure of the physes. Initial interpretation of a Merchant X ray revealed medial patellar tilt and subluxation with irregularity of the right medial patellar facet. Physical examination revealed symmetrical range of motion (+5/140°), no knee effusion, and pain with lateral glide of the right patella (i.e., positive Apprehension Test). Maximal muscle testing of the quadriceps revealed 4/5 with anterior knee pain on left and 5/5 without pain on the right. The left patella tracked laterally with palpable crepitus. In addition, both patellae were laterally positioned and externally rotated on visual inspection.

Rehabilitative Intervention

The patient was treated six times in physical therapy during a 6-week period. Physical therapy consisted of patellar taping (5), quadriceps setting at 0°, straight-leg raises (2–5 lb), leg presses, proprioception exercises, and knee extension

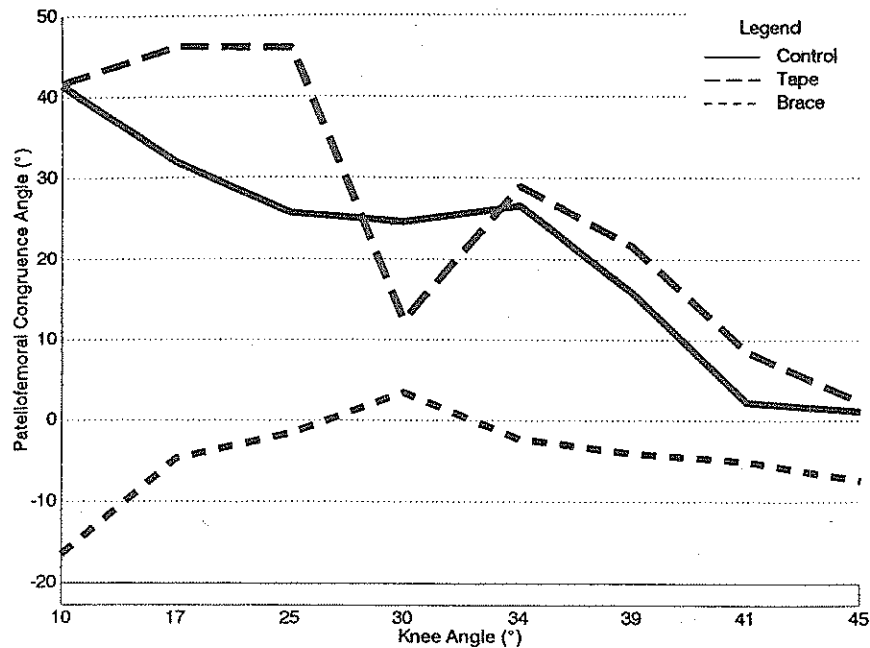


Figure 4 — Patellofemoral congruence angle.

number the greater the medial patellar tilt. The LPD values ranged from 8.23 to 24.19 mm in the control condition, 4.68 to 9.44 mm with the brace, and 7.48 to 24.192 mm for patellar taping (Figure 6). A positive LPD represents a lateralized patella. The larger the value, the more lateral the patella. During an 8-in. step-down, VAS pain ratings were 90 mm for control condition, 4 mm for bracing condition, and 5 mm for taping condition (Figure 7).

Discussion

Results of this case study reveal that a patellar brace with a lateral crescent pad and dynamic straps improved (medialized) patellar alignment within and out of the femoral sulcus compared to patellar taping and the control condition. We were unable to locate studies that quantified the effect of patellar bracing on patellar position. Palumbo (5) described his knee brace and reported that 93% of the patients using this brace reported “the brace helped alleviate or significantly reduce symptoms” (p. 48). He sent a questionnaire to 106 patients, of which 62 responded. Eighty percent of the patients improved with the brace and physical therapy as reported by the questionnaire. Twenty percent of the patients with patellar subluxation underwent a surgical treatment. No quantification of patellar position was provided. Palumbo (5) did, however, present three radiographs demonstrating the effect of no brace and bracing, immediate and long term (6 months), on patellar position. At a 6-month follow-up radiograph with no brace, the patella appeared to be in a more medial position. Our results are in agreement

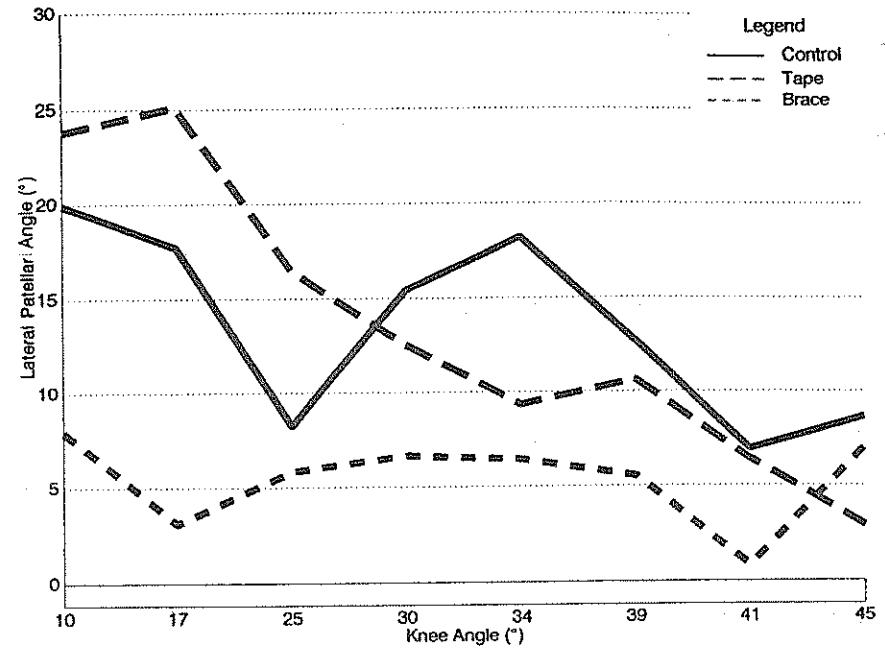


Figure 5 — Lateral patellar angle.

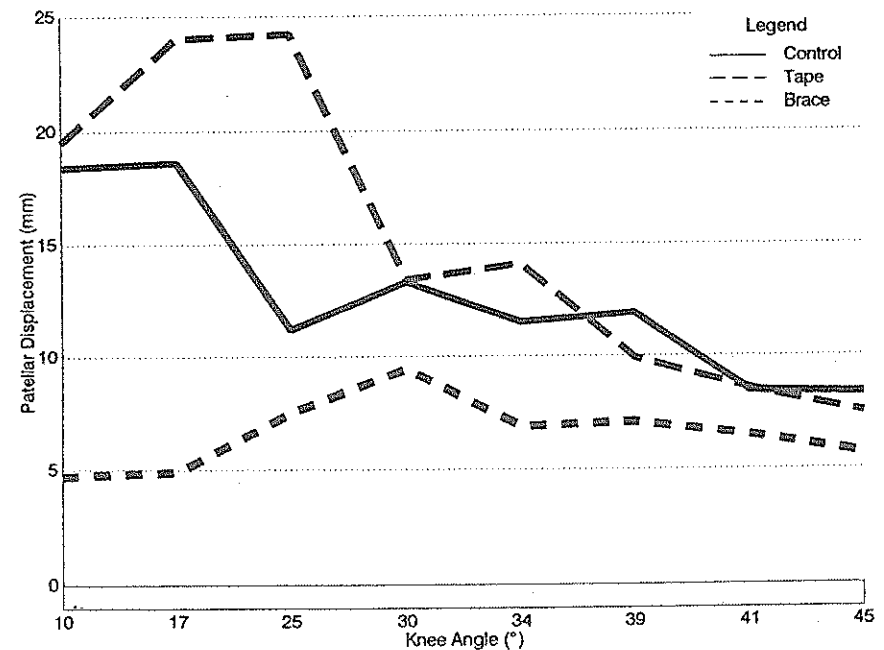


Figure 6 — Lateral patellar displacement.

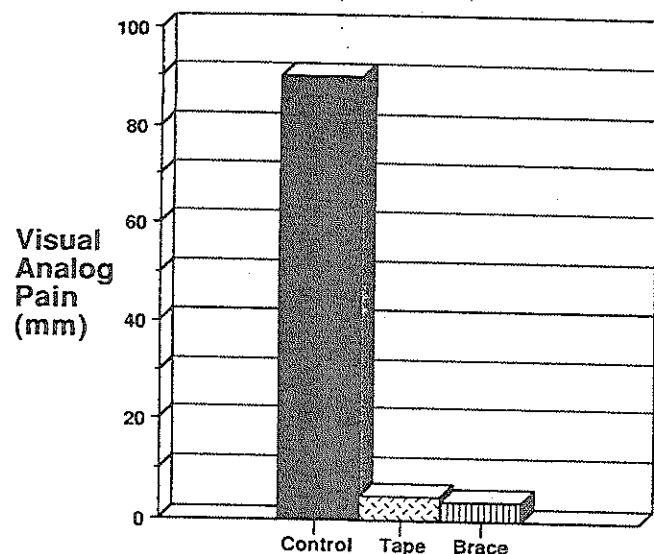


Figure 7 — Visual analog pain ratings.

with Palumbo's radiographs, demonstrating medialization for the patella with a patellar brace.

Failure of patellar taping to change patellar position in our study is consistent with Brockrath et al.'s (1) study, which showed no change in PFC angles or patellar rotation angles in 12 patients with anterior knee pain syndrome. Both findings are in disagreement with McConnell (4), who speculated that patellar taping facilitates the VMO and improves patellar alignment. Moreover, during the 0–25° arc, taping actually increased the LPD and PFC values (Figures 4 and 6), indicating a more lateral patella, and it increased LPA (Figure 5), indicating a more medial tilted patella.

In addition, the patient in our study reported a reduction of pain while wearing the brace during an 8-in. step-down procedure compared to the control condition. This reduction in pain while the subject was wearing the brace might be explained by the more medial alignment of the patella within and out of the femoral sulcus, which should provide more evenly distributed forces to the patella, hence removing excessive pressure from degraded articular cartilage. However, the patient also reported a reduction of pain when the patella was taped, even when the patella was not medialized. This finding is in agreement with McConnell's (4) report of significant pain reduction after patellar taping. The reduction of pain after taping is difficult to explain since patellar position didn't change. Brockrath et al. (1) postulated that sensory input from the tape (large fiber input) may be responsible for pain reduction after patellar taping. More research is needed to explain the reduction of pain with patellar taping. Likewise, the mechanism for reduced pain following corrected patellar tracking is unclear.

Recommendations and Limitations

We recommend patellar bracing for patients with patellar instability and pain. Patellar bracing is much easier for the patient to apply compared to patellar

taping, which requires instruction and much greater compliance. Also significant in this age of cost containment is the fact that patellar taping supplies for 1 month (four rolls of tape) cost \$74, compared to \$68 for a patellar brace (Palumbo). Obviously, the costs of the tape and brace will vary depending on the facility, but we feel the brace is the most cost-effective choice. In addition, the ability of patients to correctly perform patellar taping has not been reported.

Case studies have limited generalizability. For example, will all patients with patellar instability respond favorably to patellar bracing? We speculate that patient response will vary. Future studies are needed to determine the effect of patellar bracing and taping on different subjects. Furthermore, static unloaded patellar positioning may yield incomplete information compared to dynamic closed kinetic chain positioning as required in functional activities. Specifically, a comparison of patellar position in both the open and closed chain during taping and bracing is needed.

Conclusion

Patellar bracing was more effective than patellar taping in medializing the patella and decreasing medial patellar tilt in this patient. Both taping and bracing significantly reduced pain during an 8-in. step-down. The mechanism for the pain reduction during taping and bracing needs further study. Because case studies have limited generalizability, more research is needed to determine the effect of patellar bracing and taping on different subjects.

References

1. Brockrath, K., C. Wooden, T. Worrell, C. Ingersoll, and J. Farr. Effects of patella taping on patellar position and perceived pain. *Med. Sci. Sports Exerc.* 25(9):989-992, 1993.
2. Doucette, S.A., and E.M. Goble. The effect of exercise on patellar tracking in lateral patellar compression syndrome. *Am. J. Sports Med.* 20(4):434-440, 1992.
3. Ingersoll, C.D., and K.L. Knight. Patellar location changes following EMG biofeedback or progressive resistive exercises. *Med. Sci. Sports Exerc.* 23(1):1122-1127, 1991.
4. McConnell, J.S. The management of chondromalacia patellae: A long term solution. *Aust. J. Physiother.* 32:215-223, 1986.
5. Palumbo, P.M. Dynamic patellar brace: A new orthosis in the management of patellofemoral disorders. *Am. J. Sports Med.* 9(1):45-49, 1981.
6. Westfall, D.C., and T.W. Worrell. Anterior knee pain syndrome: Role of the vastus medialis oblique. *J. Sport Rehabil.* 1:317-325, 1992.

Acknowledgments

We would like to thank St. Francis Hospital, Beech Grove, Indiana, for providing the MRI time for this project; Paul Minus, R.T., for his assistance with this MRI project; DynOrthotics LP, Vienna, Virginia, for providing the Palumbo Brace; and Fred Loeffler, P.T., of Indianapolis Physical Therapy and Sports Medicine, for his help.